

## Case Report

## Open Access

### Laparoscopic management of mesenteric cyst: a case report

Theodoros D Theodoridis\*, Leonidas Zepiridis, Dimitrios Athanatos, Filippos Tzevelekis, Diamantis Kellartzis and John N Bontis

Address: First Department of Obstetrics and Gynaecology, Aristotle University of Thessaloniki, 'Papageorgiou' Hospital, Thessaloniki, Greece

Email: Theodoros D Theodoridis\* - theodtheo@yahoo.gr; Leonidas Zepiridis - lzepe@hol.gr; Dimitrios Athanatos - dimitriosathanatos@hotmail.com; Filippos Tzevelekis - ftzev@med.auth.gr; Diamantis Kellartzis - john\_kellar@hotmail.com; John N Bontis - bontis@med.auth.gr

\* Corresponding author

Published: 8 February 2009

Received: 17 November 2008

Cases Journal 2009, 2:132 doi:10.1186/1757-1626-2-132

Accepted: 8 February 2009

This article is available from: <http://www.casesjournal.com/content/2/1/132>

© 2009 Theodoridis et al; licensee BioMed Central Ltd.

This is an Open Access article distributed under the terms of the Creative Commons Attribution License (<http://creativecommons.org/licenses/by/2.0>), which permits unrestricted use, distribution, and reproduction in any medium, provided the original work is properly cited.

#### Abstract

Mesenteric cysts are rare intra-abdominal lesions with variable clinical symptoms and signs that make pre-operative diagnosis difficult. Optimal treatment is surgical excision of the cyst with laparotomy or laparoscopy. We present a case of mesenteric cyst that was misdiagnosed as para-ovarian cyst and managed laparoscopically by gynaecologists.

#### Introduction

Mesenteric cysts are rare intra-abdominal tumors with prevalence 1:100.000 in adults and 1:20.000 in children [1,2]. They are usually benign and asymptomatic, but occasionally they present with various, non-specific symptoms. Due to the rarity of this entity and the lack of specific symptoms, correct pre-operative diagnosis is difficult. Complete surgical excision is the treatment of choice. This can be accomplished by laparotomy or by minimally invasive surgery.

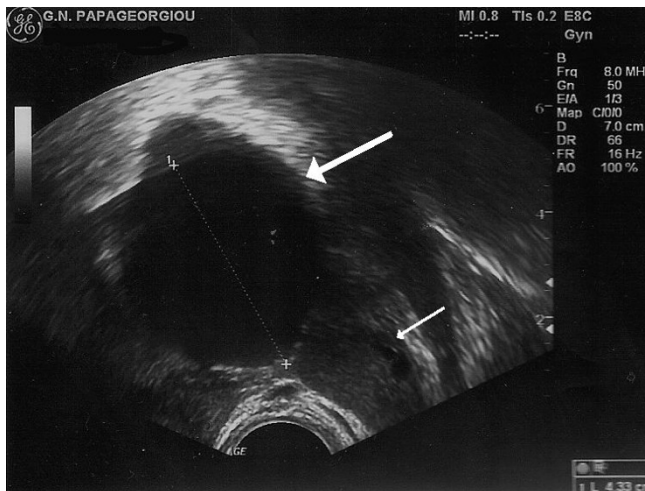
We present a case of mesenteric cyst that was misdiagnosed as para-ovarian cyst and managed successfully laparoscopically.

#### Case report

A 30 years old, G0P0, Caucasian, housewife, referred to our department for surgical management of a left-sided para-ovarian cyst. Her only complaint was a vague, non-specific lower abdominal pain for the previous 6 months. She had an appendectomy at the age of 12 but the rest of her medical and family history were unremarkable.

Clinical examination was also unremarkable and her blood tests were normal. Bimanual gynaecological examination revealed a palpable, motile tumor in the left adnexae. Trans-vaginal ultrasound revealed a 4.33 × 4.84 × 4.52 cm thin-walled, simple, unilocular cyst, located next to the left ovary (Fig. 1). A para-ovarian cyst was the most likely diagnosis, hence a laparoscopic removal was proposed.

At laparoscopy a simple cyst was seen lying inferior and lateral to the aortic bifurcation, arising from the mesentery of the descending colon, in contact with left ovary. During exploration the cyst was found movable, attached only posteriorly to the mesentery. The cyst was carefully dissected with the assistance of ultrasonic harmonic scalpel (Ethicon, Endo-Surgery, LLC) and removed intact. Thorough examination of the integrity of the bowel and the mesenteric vessels was followed. The specimen was placed in an endobag, aspirated and extracted from the peritoneal cavity through the 10 mm suprapubic port. Histopathological examination revealed a simple, benign mesothelial cyst of the mesentery.



**Figure 1**  
**Thick arrow: cystic structure misdiagnosed as para-ovarian cyst in ultrasound. Thin arrow: left ovary.**

The patient's post-operative period was uneventful and she was discharged free of symptoms the following day. One year after the surgery she remains completely asymptomatic.

### Discussion

Mesenteric cysts are quite rare intra-abdominal lesions. Italian anatomist Benevanni first described this entity performing an autopsy in an 8 years old boy in 1507 [3].

In most of the cases the cysts are located in the mesentrium of small intestine, but they can also be found in the descending colon and rectum [4]. Their histopathological classification is designated by the cell type of the inner cyst wall layer, so mesenteric cysts can be of lymphatic, mesothelial, enteric, urogenital origin, or nonpancreatic pseudocysts [1,2]. Fortunately they behave mostly as benign tumors, while malignancy accounts for 3% of the cases, arising gradually or de novo [5].

Mesenteric cysts size ranges between a few centimeters and 10 cm [6]. Usually they do not cause specific symptoms. Clinical presentations include common symptoms of the gastrointestinal tract and rarely they can be complicated with rupture, torsion or intestinal obstruction causing acute and intense symptoms.

Correct pre-operative diagnosis is quite difficult due to the rarity of the entity and the lack of specific symptoms and signs. It can be achieved when the physician is alerted concerning this condition and includes it in the differential diagnosis of intra-peritoneal cysts. Clinical imaging (ultrasound, CT scan or Magnetic Resonance Imaging-

MRI) [6] may aid in the correct diagnosis. Careful interpretation of images is essential. Despite our experience this cystic structure was misdiagnosed as para-ovarian in origin, hence we believe that CT scan should be considered more often in preoperative management.

The treatment of choice is complete surgical excision of the cyst. This can be done either by laparotomy or laparoscopy [7,8]. The decision regarding the surgical approach depends on the size of the cyst, its location in the abdominal cavity and eventually the level of surgeon's experience in minimal access surgery. In our case the procedure was performed by experienced Gynaecological endoscopists.

### Conclusion

Mesenteric cysts, although quite rare tumors of the mesentrium, must always be considered in differential diagnosis of pelvic cystic lesions. Laparoscopic enucleation of mesenteric cysts is feasible and should be considered as the treatment of choice.

### Consent

Written informed consent was obtained from patient – in her native language – for publication of this case report and accompanying image. Copy of the written consent is available for review by the Editor-in-Chief of this journal.

### Competing interests

The authors declare that they have no competing interests.

### Authors' contributions

TDT and LZ conceived the study and participated in patient management and surgery, acquisition of data, interpretation of data, and were major contributors in writing the manuscript. DA participated in patient management, acquisition of data, and drafting of the manuscript. FT and DK revised critically the manuscript adding substantial intellectual content. JB coordinated the study and patient management and revised critically the manuscript. All authors have read and approved the final manuscript. The manuscript is not under consideration and has not been published by another journal.

### References

1. De Perrot M, Bründler MA, Tötsch M, et al.: **Mesenteric cysts. Toward less confusion?** *Dis Surg* 2000, **17(4)**:323-328.
2. Kwan E, Lau H, Yuen WK: **Laparoscopic resection of a mesenteric cyst.** *Gastrointest Endosc* 2004, **59(1)**:154-156.
3. Braquehage J: **Des kystes du mesentery.** *Arch Gen* 1892, **170**:291.
4. Sahin Dursun Ali, Akbulut Gokhan, Saykol Volkan, San Osman, Tokyol Gigde, Dilek Osman Nuri: **Laparoscopic enucleation of mesenteric cyst: A case report.** *The Mount Sinai J of Med* 2006, **73(7)**:1019-1020.
5. Kurtz RJ, Heimann TM, Beck AR, Holt J: **Mesenteric and Retroperitoneal Cysts.** *Ann Surg* 1986, **203(1)**:109-112.
6. Sato M, et al.: **Mesenteric cyst: sonographic findings.** *Abdom Imaging* 2000, **25**:306-310.
7. Trompetas V, Varsamidakis N: **Laparoscopic management of mesenteric cysts.** *Surg Endosc* 2003, **17**:2036.

8. Dequanter D, Lefebvre JC, Belva P, Takieddine M, Vaneukem P: **Mesenteric cysts: A case treated by laparoscopy and a review of the literature.** *Surg Endosc* 2002, **16(10)**:1493.

Publish with **BioMed Central** and every scientist can read your work free of charge

*"BioMed Central will be the most significant development for disseminating the results of biomedical research in our lifetime."*

Sir Paul Nurse, Cancer Research UK

Your research papers will be:

- available free of charge to the entire biomedical community
- peer reviewed and published immediately upon acceptance
- cited in PubMed and archived on PubMed Central
- yours — you keep the copyright

Submit your manuscript here:  
[http://www.biomedcentral.com/info/publishing\\_adv.asp](http://www.biomedcentral.com/info/publishing_adv.asp)

