

## Case report

**Irreducible distal radial fracture due to extensor pollicis longus tendon interposition: a case report**

Paraskumar Mohanlal\* and Sunil Jain

Address: Department of Trauma and Orthopaedics, Medway Maritime Hospital, Medway, ME7 5NY, UK

Email: PM\* - drmpkumar@hotmail.co.uk; SJ - sunil.jain@medway.nhs.uk

\* Corresponding author

Published: 3 June 2009

Received: 24 March 2009

Cases Journal 2009, 2:6822 doi: 10.1186/1757-1626-2-6822

Accepted: 16 May 2009

This article is available from: <http://casesjournal.com/casesjournal/article/view/6822>

© 2009 Mohanlal and Jain; licensee Cases Network Ltd.

This is an Open Access article distributed under the terms of the Creative Commons Attribution License (<http://creativecommons.org/licenses/by/3.0>), which permits unrestricted use, distribution, and reproduction in any medium, provided the original work is properly cited.**Abstract**

Various causes have been reported for irreducible fractures of the distal radius. Most of them have been reported in children.

We report a case of irreducible distal radial fracture in an 18-year-old Caucasian male patient. The fracture was not reducible by closed methods and extensor pollicis tendon was found to be interposed during surgical intervention. At one year follow-up, the patient had good radiological evidence of fracture healing and a good functional outcome.

This case report highlights the need for a high index of suspicion to rule out soft tissue interposition in cases of irreducible distal radial fractures and a low threshold for open reduction.

**Introduction**

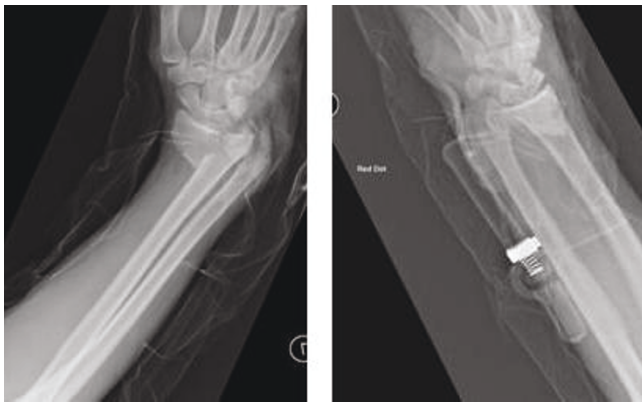
Irreducible distal radial fracture due to tendon interposition is uncommon. Most of them have been reported in children. Various causes have been cited including interposition of extensor tendons [1], flexor tendons [2], periosteal flap [3] and soft tissues [4]. Such injuries appear to be common than is reported in the literature. Recognition is necessary to avoid complications of inadequate reduction.

**Case presentation**

An 18-year-old Caucasian male patient presented with a Grade I open distal radial fracture following a road traffic accident. He was hemodynamically stable with no evidence of neurovascular compromise to the limb. Radiographs showed a comminuted, extraarticular volarly

displaced, sheer type metaphyseal distal radial fracture associated with fracture of ulnar metaphysis (Figure 1). Patient did not have any other comorbidities and no known allergies to any medication.

The fracture could not be reduced by closed manipulation and hence a volar approach was used for open reduction. However, reduction was still not possible and hence a dorsal approach was used to explore the cause of difficult fracture reduction. The tendon of extensor pollicis longus was found to be interposed in the fracture site. The tendon was released from the fracture site following which the fracture was well reduced. The radial fracture was stabilised with a volar plate and the ulnar fracture with a 'K' wire. A prophylactic carpal tunnel decompression was performed.

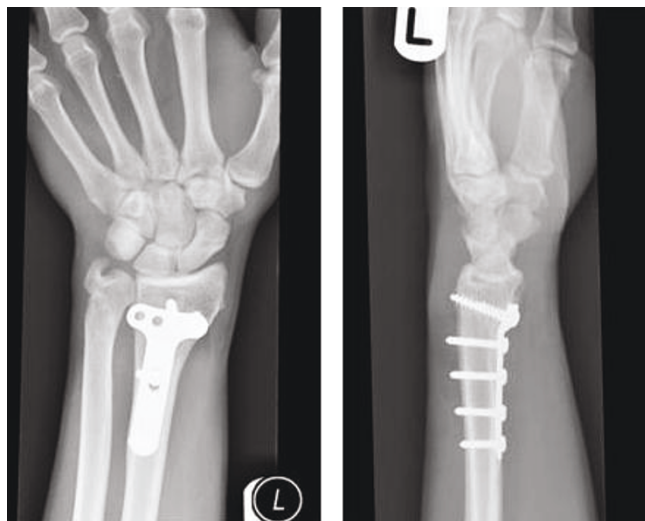


**Figure 1.** Pre-operative radiographs of the wrist showing displaced fracture of the distal radius and ulna.

Post-operatively the patient recovered well and at one year follow-up, radiographs showed good fracture healing (Figure 2) and he regained good functional recovery of the arm.

### Discussion

Irreducible fractures of distal radius due to tendon interposition are uncommon injuries in adults. Almost all cases of irreducible distal radial fractures have been reported in children with a growing physal plate. They have been attributed to interposition of various soft tissues including the flexor and extensor tendons [1-4].



**Figure 2.** Follow-up radiographs of the same patient showing good radiological evidence of union of both radial and ulnar fractures.

Manoli [3] reported a case of distal radial epiphyseal injury complicated by entrapment of flexor digitorum profundus tendon causing difficulty in reduction. Extensor tendon interposition between the metaphysis and epiphysis of both the ulna and radius was reported by Karlsson et al [1]. Ooi et al [4] described two consecutive cases of Galeazzi-equivalent fracture in children associated with tendon interposition at the fracture site and reported good functional outcome after open reduction and internal fixation. Periosteal flap causing difficult fracture reduction in Salter Harris type II distal radial injury was reported by Lesko et al [3].

In our case the patient had attained skeletal maturity and sustained this fracture due to high velocity injury. The mechanism of injury due to fall from a motor bike, fracture of both distal radius and ulna, associated soft tissue disruption, and a shear type fracture configuration of the radius would have caused rupture of the extensor retinaculum and consequent entrapment of the extensor pollicis longus tendon at the fracture site. This was identified by dorsal approach during open reduction. Release of the tendon resulted in satisfactory fracture reduction and follow-up radiographs showed good radiological evidence of union.

### Conclusion

This case report highlights the need for a high index of suspicion to rule out soft tissue interposition in cases of irreducible distal radial fractures and a low threshold for open reduction.

### Abbreviations

None.

### Consent

Written informed consent was obtained from the patient for publication of this case report and accompanying images. A copy of the written consent is available for review by the Editor-in-Chief of this journal.

### Competing interests

The authors declare that they have no competing interests.

### Authors' contributions

Both PM and SJ have been involved in the initial management of the patient, surgical treatment, follow-up, literature search and preparation of the manuscript and images.

### References

1. Karlsson J, Appelqvist R: **Irreducible fracture of the wrist in a child. Entrapment of the extensor tendons.** *Acta Orthop Scand* 1987 Jun, **58**:280-281.

2. Manoli A: **Irreducible fracture-separation of the distal radial epiphysis. Report of a case.** *J Bone Joint Surg Am* 1982, **64**: 1095-1096.
3. Lesko PD, Georgis T, Slabaugh P: **Irreducible Salter-Harris type II fracture of the distal radial epiphysis.** *J Pediatr Orthop* 1987, **7**: 719-721.
4. Ooi LH, Toh CL: **Galeazzi-equivalent fracture in children associated with tendon entrapment-report of two cases.** *Ann Acad Med Singapore* 2001, **30**:51-54.

### Do you have a case to share?

Submit your case report today

- Rapid peer review
- Fast publication
- PubMed indexing
- Inclusion in Cases Database

**Any patient, any case, can teach us something**



**CASES  
NETWORK**

[www.casesnetwork.com](http://www.casesnetwork.com)