



Case report

## **A severe coarctation of aorta in a 72-year-old female: a case report**

Evangelos Kountouris, Thomas Potsis\*, Dimitrios Nikas and Konstantinos Siogas

Address: Department of Cardiology, "G.Hatzikosta" General Hospital of Ioannina, 45001 Ioannina, Greece

Email: EK - kounte@otenet.gr; TP\* - th.potsis@yahoo.gr; DN - dnikas@uoi.gr; KS - ksiog@otenet.gr

\* Corresponding author

Received: 2 March 2009 Accepted: 11 May 2009 Published: 15 June 2009

*Cases Journal* 2009, **2**:6308 doi: 10.4076/1757-1626-2-6308

This article is available from: <http://casesjournal.com/casesjournal/article/view/6308>

© 2009 Kountouris et al; licensee Cases Network Ltd.

This is an Open Access article distributed under the terms of the Creative Commons Attribution License (<http://creativecommons.org/licenses/by/3.0>), which permits unrestricted use, distribution, and reproduction in any medium, provided the original work is properly cited.

### **Abstract**

Aortic coarctation is a congenital malformation of the aorta usually diagnosed and corrected early in life. Long-term survival is exceptional in patients with untreated aortic coarctation. In this case report, we present a late diagnosis of aortic coarctation in a 72-year-old female. Our patient was relatively asymptomatic until she presented with exertional dyspnea and fatigue in her seventh decade of life. The patient was managed conservatively with aggressive antihypertensive medication. After the 1-year follow-up visit, the patient was in good clinical condition, without, however, adequate control of blood pressure.

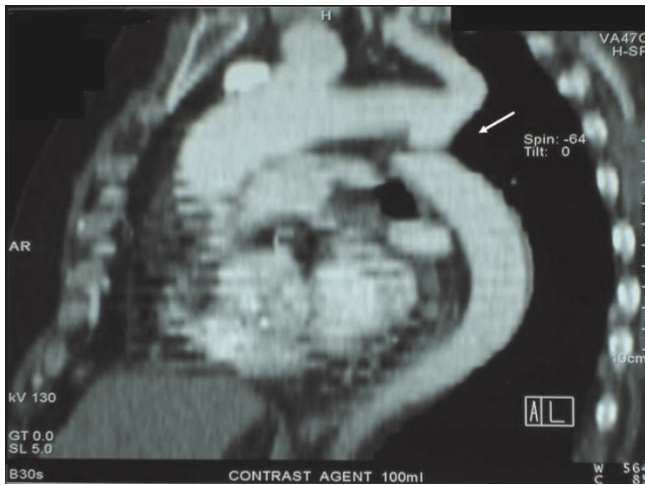
### **Case presentation**

A 72-year-old obese Caucasian woman was referred to our hospital because of increasing fatigue and exertional dyspnea. She had been well until 10 months previously. The patient had a medical history of diabetes, dyslipidemia and hypertension. Her hypertension was poorly controlled despite a combination of antihypertensive agents (b-blocker, diuretic, calcium channel blocker and angiotensin receptor blocker).

Physical examination showed blood pressure 125/75 in both arms and a heart rate of 77 beats/minute. A systolic ejection murmur was heard at the left upper sternal border. Femoral pulses were palpable bilaterally but weak and delayed compared to the brachial pulses. Electrocardiography revealed sinus rhythm and left bundle branch block. A cardiac silhouette at the upper limits of normal and notching of the ribs were observed on the

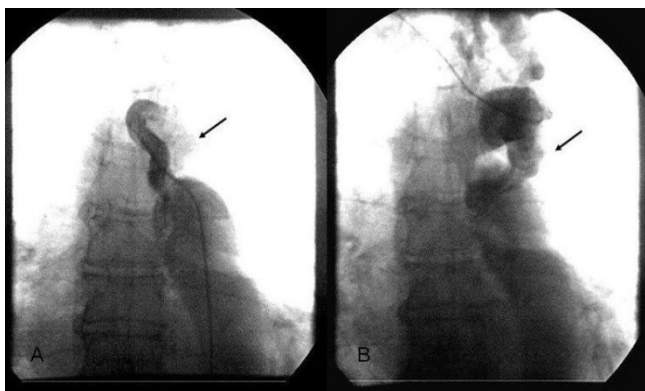
chest radiography. Her echocardiogram showed dilatation of ascending aorta (42 mm), tricuspid sclerotic aortic valve with mild stenosis, moderate systolic dysfunction of the left ventricle (ejection fraction 45-50%) and a turbulent jet at the distal aortic arch. Although it is extremely rare at this age, aortic coarctation was suspected and thoracic computed tomography (CT) angiography was performed. The CT angiogram disclosed severe coarctation of aorta distal to the origin of the left subclavian artery (Figure 1) with post-stenotic dilatation. Compensatory dilatation of the intercostals arteries was noted.

The patient underwent cardiac catheterization to evaluate her coronary artery disease and the severity of the coarctation. Coronary angiography performed using a 5Fr pigtail catheter via right radial artery showed coronary arteries of normal distribution without significant atheromatosis. Aortography revealed a significant, tortuous,

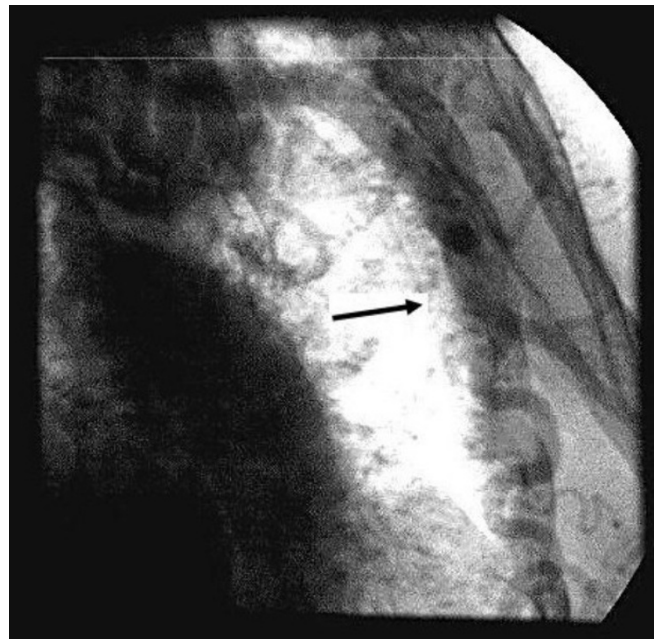


**Figure 1.** CT angiogram revealing severe stenosis of the aorta below the origin of the subclavian artery.

and long stenosis of the aorta just below the origin of the left subclavian artery indicating typical angiographic image for high-grade, postductal coarctation of aorta (Figure 2A,B). A marked development of the left internal mammary artery was noted (Figure 3). Another 5Fr catheter was placed distally to the point of the stenosis via right femoral artery. Using both catheters, placed proximally and distally to the point of the coarctation, simultaneous pressure measurement confirmed significant pressure gradient of 44 mmHg (Figure 4). The patient was referred to the cardiothoracic surgery to evaluate her candidacy for surgical or percutaneous therapy but she refused any invasive correction. At the 1-year follow-up visit, the patient was in good clinical condition, with good effort capacity but adequate control of hypertension was not achieved.



**Figure 2 A and B.** Angiographic images showing significant stenosis in the thoracic descending aorta.

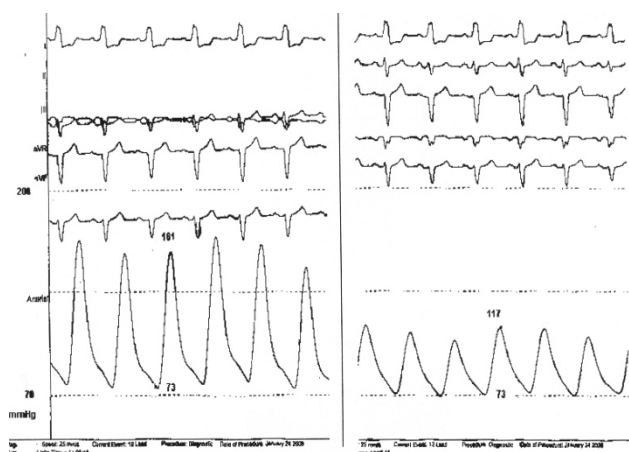


**Figure 3.** Angiographic image of the markedly developed left internal mammary artery.

### Discussion

Aortic coarctation is a congenital vascular lesion typically diagnosed in early life, accounting for 5 to 10% of all congenital cardiovascular malformations [1] but may go undetected well until adulthood. Most commonly, coarctation diagnosed at ages beyond childhood was discovered in asymptomatic patients in whom a routine physical examination disclosed upper limb hypertension with diminished or absent femoral pulses [2]. Patients with aortic coarctation rarely survive to old age for their first diagnosis [3]. Most untreated patients with coarctation of the aorta will die before 50 years of age [3]. Death in these patients is usually due to heart failure, coronary artery disease, aortic rupture/dissection, concomitant aortic valve disease, infective endarteritis/endocarditis, or cerebral hemorrhage [3,7]. There are few reports of patients first diagnosed with uncorrected aortic coarctation at very late age [4-6], and there is no consensus on how to manage them. In this report, we present the case of a 72-year-old woman first diagnosed with severe aortic coarctation. Our patient was relatively asymptomatic until she presented with fatigue and exertional dyspnea in her seventh decade of life.

Treatment of aortic coarctation consists of aggressive hypertension therapy, endocarditis prophylaxis and corrective treatment for coarctation with a high gradient. Aortic obstruction may be relieved by surgery or by transcatheter techniques. In the past, surgery has been used



**Figure 4.** Simultaneous pressure measurements at a proximal and distal point of the coarctation of the aorta.

exclusively. However, over the last 20 years, balloon angioplasty, recently associated with stenting, is a widely accepted therapeutic procedure for aortic coarctation and is recommended as the therapy of choice in experienced centers [8,9]. Despite successful repair of aortic coarctation, recurrent hypertension is common during long-term follow up.

The reported prevalence of late hypertension depends on the diagnostic criteria used and on the duration of follow up, ranging from 30% [10] to 75% [11]. Because there are only a few cases of elderly patients with uncorrected aortic coarctation, management strategies in these patients are controversial. The beneficial effect of intervention - whether surgical or transcatheter- in terms of diminished mortality in very old patients is still questionable, which makes conservative management with antihypertensive drug therapy an acceptable treatment option in such patients.

**Abbreviation**

CT, Computed Tomography.

**Consent**

Written informed consent was obtained from the patient for publication of this case report and accompanying images. A copy of the written informed consent is available for review by the Editor-in-Chief of this journal.

**Competing interests**

The authors declare that they have no competing interests.

**Authors' contributions**

EK managed the patient, performed the cardiac catheterization and involved in drafting the manuscript. TP managed the patient, analyzed and interpreted the patient

data, and he was a major contributor in writing the manuscript. DN performed the cardiac catheterization and involved in drafting the manuscript. KS searched the relative literature and critically revised the manuscript. All authors read and approved the final manuscript.

**References**

1. Grech V: **Diagnostic and surgical trends, and epidemiology of coarctation of the aorta in a population-based study.** *Int J Cardiol* 1999, **68**:197-202.
2. Warnes CA, Deanfield JE: **Congenital heart disease in adults.** In *Hurst's The Heart* Volume 2. 11th edition. Edited by Fuster V, Alexander RW, O'Rourke RA, Roberts R, King SB III, Nash IS, Prystowsky EN. New York: McGraw Hill Professional; 2004:1866.
3. Campbell M: **Natural history of coarctation of the aorta.** *Br Heart J* 1970, **32**:633-640.
4. Convens C, Vermeersch P, Paelinck B, Van den Heuvel P, Van den Branden F: **Aortic coarctation: a rare and unexpected cause of secondary arterial hypertension in the elderly.** *Cathet Cardiovasc Diagn* 1996, **39**:71-74.
5. Miro O, Jimenez S, Gonzalez J, De Caralt TM, Ordi J: **Highly effective compensatory mechanisms in a 76-year-old man with a coarctation of the aorta.** *Cardiology* 1999, **92**:284-286.
6. Cevik S, Izgi C, Cevic C: **Asymptomatic severe aortic coarctation in an 80-year-old man.** *Tex Heart Inst J* 2004, **31**:429-434.
7. Jenkins NP, Ward AR: **Coarctation of the aorta: natural history and outcome after surgical treatment.** *QJM* 1999, **92**:365-371.
8. Diethrich EB, Heuser RR, Cardenas JR, Eckert J, Tarlian H: **Endovascular techniques in adult aortic coarctation: the use of stents for native and recurrent coarctation repair.** *J Endovasc Surg* 1995, **2**:183-188.
9. Fawzy ME, Awad M, Hassan W, AL Kadhi Y, Shoukri M, Fadley F: **Long-term outcome (up to 15 years) of balloon angioplasty of discrete native coarctation of the aorta in adolescents and adults.** *J Am Coll Cardiol* 2004, **43**:1062-1067.
10. Cohen M, Fuster V, Steele PM, Driscoll D, McGoon DC: **Coarctation of the aorta: long-term follow-up and prediction of outcome after surgical correction.** *Circulation* 1989, **80**:840-845.
11. Clarkson PM, Nicholson MR, Barratt-Boyes BG, Neutze JM, Whitlock RM: **Results after repair of coarctation of the aorta beyond infancy: a 10 to 28 year follow-up with particular reference to late systemic hypertension.** *Am J Cardiol* 1983, **51**:1481-1488.

**Do you have a case to share?**

Submit your case report today

- Rapid peer review
- Fast publication
- PubMed indexing
- Inclusion in Cases Database

**Any patient, any case, can teach us something**



**CASES NETWORK**

www.casesnetwork.com