

Case Report

Open Access

## Lipoid pneumonia presenting as non resolving community acquired pneumonia: a case report

Vijay Hadda<sup>1</sup>, Gopi C Khilnani\*<sup>1</sup>, Ashu S Bhalla<sup>2</sup> and Sandeep Mathur<sup>3</sup>

Address: <sup>1</sup>Department of Medicine, All India Institute of Medical Sciences, New Delhi, 110029, India, <sup>2</sup>Department of Radio diagnosis, All India Institute of Medical Sciences, New Delhi, 1110029, India and <sup>3</sup>Department of Pathology, All India Institute of Medical Sciences, New Delhi, 110029, India

Email: Vijay Hadda - vijayhadda@yahoo.com; Gopi C Khilnani\* - gckhil@hotmail.com; Ashu S Bhalla - ashubhalla1@yahoo.com; Sandeep Mathur - drsunnymathur@yahoo.com

\* Corresponding author

Published: 16 December 2009

Received: 30 November 2009

Cases Journal 2009, 2:9332 doi:10.1186/1757-1626-2-9332

Accepted: 16 December 2009

This article is available from: <http://www.casesjournal.com/content/2/1/9332>

© 2009 Hadda et al; licensee BioMed Central Ltd.

This is an Open Access article distributed under the terms of the Creative Commons Attribution License (<http://creativecommons.org/licenses/by/2.0>), which permits unrestricted use, distribution, and reproduction in any medium, provided the original work is properly cited.

### Abstract

**Introduction:** Lipoid pneumonia is a rare form of pneumonia caused by inhalation or aspiration of fat containing substances like, petroleum jelly, mineral oils, few laxatives etc. It usually presents as insidious onset chronic respiratory illness simulating interstitial lung diseases. Rarely, it may present as an acute respiratory illness, specially, when exposure to fatty substance is acute and/or massive. Radiologically, it may mimic carcinoma, acute or chronic pneumonia, ARDS, or a localized granuloma. Diagnosis of LP requires demonstration of lipid laden macrophages in sputum, bronchoalveolar lavage fluid or fine needle aspiration cytology/biopsy from lung lesion. Treatment of this illness is poorly defined and constitutes supportive therapy and corticosteroids.

**Case presentation:** A 20-year old Indian farmer was referred to us with a diagnosis of non resolving community acquired pneumonia. Respiratory examination revealed signs of consolidation. Chest radiograph revealed findings suggestive of bilateral consolidation. Sputum and blood culture were sterile. He was treated with prolonged course of various antibiotics without any significant response. For evaluation of non resolving pneumonia fiberoptic bronchoscopy was done. Bronchoalveolar lavage fluid and biopsy from lung lesion showed lipid laden macrophages. Hence diagnosis of lipoid pneumonia was made. Patient was treated with course of corticosteroids with good response. Literature on this rare entity is discussed.

**Conclusion:** Lipoid pneumonia is a rare form of pneumonia which rarely present acutely resembling community acquired pneumonia and requires high degree of suspicion for diagnosis. Its treatment is difficult and poorly defined. However, prolonged corticosteroids may be effective.

### Introduction

Lipoid pneumonia (LP) is a rare form of pneumonia caused by inhalation or aspiration of a fatty substance. This entity was first described in initial half of twentieth century [1]. It usually presents as a chronic respiratory disease with symptoms of shortness of breath and cough.

However, it may present as acute respiratory illness when exposure is to large quantity of mineral oil [2,3]. This entity does not have characteristic clinical or radiological features. Therefore, awareness of this type of pneumonia is important as diagnosis requires a high degree of clinical suspicion. It should be considered in the differential diag-

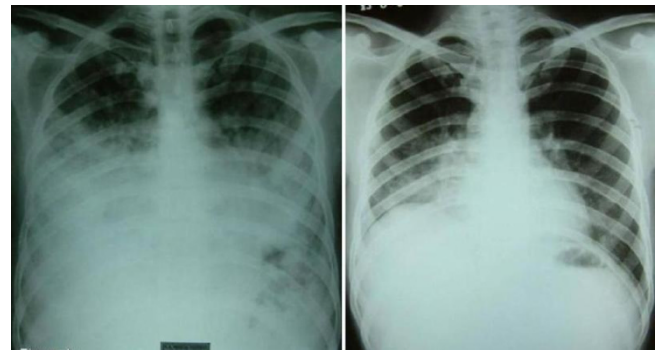noses of any acute or chronic respiratory condition in cases with history of exposure to fatty substances. The diagnosis of acute LP, in absence of history of exposure to fatty substances, may be very difficult. However, early diagnosis and timely treatment is important for better outcome. In suspected cases, diagnosis can be established by demonstrating lipid laden macrophages in various specimens like sputum, bronchoalveolar lavage, lung biopsy [4,5]. We present a case with acute LP with acute lung injury. The available literature on this rare entity is discussed.

### Case presentation

A 20 years old Indian farmer was referred to us from another hospital with a diagnosis of bilateral non resolving pneumonia. This patient was admitted in another hospital located about 250 kilometers from Delhi with complaints of acute onset high grade fever with chills, cough with expectoration, shortness of breath and bilateral pleuritic chest pain. There was no hemoptysis. He was treated in that hospital with antibiotics (details not available) and supportive therapy for 8 days without any response. He was referred to our hospital with diagnosis of non resolving community acquired pneumonia. He presented to our hospital with high grade fever, cough with profuse expectoration, dyspnea, and bilateral pleuritic chest pain. There was no history of bowel or urinary symptoms. On examination, patient was dyspneic and tachypneic with respiratory rate of 36/minute. He was febrile with temperature of 103 °F. His pulse rate was 120/minute and blood pressure was 100/60 mm of Hg. There was no pallor, icterus, cyanosis, or lymphadenopathy. Respiratory system examination revealed bronchial breathing in interscapular and infrascapular region on left side of the chest. Along with it there were extensive bilateral coarse crepitations. Examination of other systems including cardiovascular, abdominal and nervous system was normal.

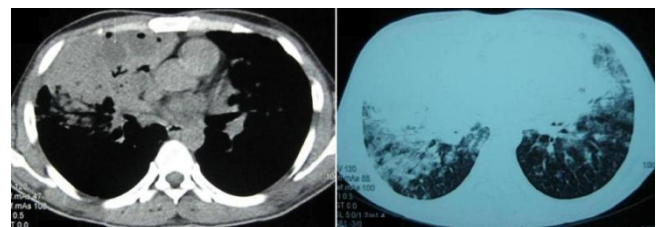
Blood investigations revealed hemoglobin of 12.0 gm/dl, leukocyte counts of 21,400/dl with 89% neutrophils, and normal platelets ( $310 \times 10^3$ /dl). Arterial blood gas analysis on  $\text{FiO}_2$  of 0.3 revealed - pH of 7.4,  $\text{pO}_2$  of 70.4 mm of Hg,  $\text{pCO}_2$  of 37.6 mm of Hg and oxygen saturation ( $\text{SaO}_2$ ) of 94%.  $\text{PaO}_2/\text{FiO}_2$  was 234.6 indicating acute lung injury. Blood urea (34 mg/dl) and creatinine (0.9 mg/dl) were normal. Liver function tests showed normal bilirubin and mild hepatitis with SGOT and SGPT of 90 and 53 IU, respectively. Blood and sputum cultures were negative for any growth. X-ray chest revealed bilateral middle and lower zone consolidation (Figure 1a).

He was treated with various intravenous (IV) antibiotics including piperacillin-tazobactam, azithromycin, cefoperazone-sulbactam, amikacin, and clindamycin. He also

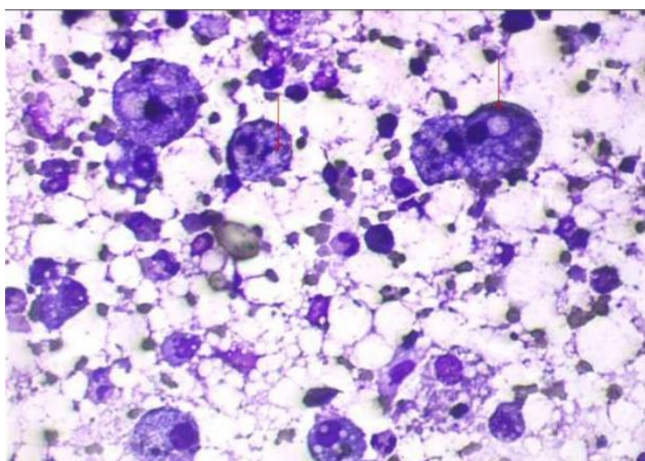


**Figure 1**  
Frontal chest radiograph (figure 1a) reveals extensive consolidation involving mid and lower zones of bilateral lung fields. Follow up chest radiograph (figure 1b) obtained three months later shows significant clearing of consolidation.

required oxygen supplementation with  $\text{FiO}_2$  of 0.3 to maintain his  $\text{SaO}_2$  in the range of 92 - 94%. Fever settled after six days of hospitalization, however, patient consistently had persistent crepitations, bronchial breathing, infiltrates on chest X-ray and raised total leukocyte count (TLC) in the range of 15400 to 26400/dl. Therefore, patient was subjected to computer tomographic (CT) scan of chest (Figure 2a and 2b) which revealed consolidation in the right middle lobe and lower lobe and also left lung. Few low density areas were seen within the right middle lobe. Patient underwent fiberoptic bronchoscopy (FOB) with bronchoalveolar lavage (BAL) and transbronchial lung biopsy (TBLB) from right lower lobe. FOB showed normal airways. BAL fluid was sterile on culture. Staining and culture for mycobacteria and fungi were negative. BAL fluid cytology showed multiple lipid laden macrophages (Figure 3). TBLB showed lung parenchyma infiltrated with foamy macrophages, lymphocytes and occasional neutrophils in the alveolar spaces.

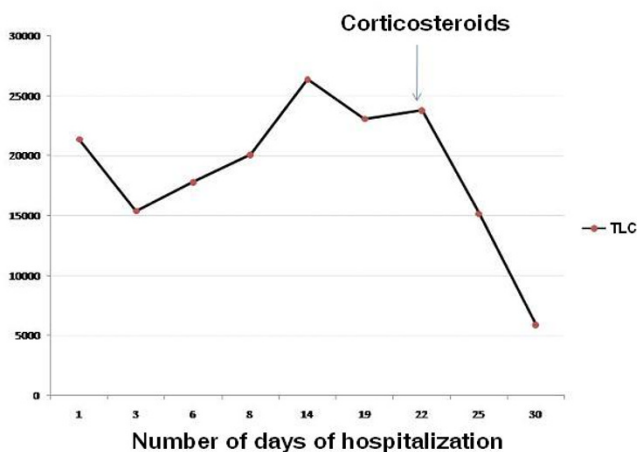


**Figure 2**  
Mediastinal (Figure 2a) and lung window (figure 2b) of non-contrast computer tomographic scan of chest reveals consolidation in the right middle lobe, lower lobe, and also left lung. Few low density areas (arrow) are seen within the middle lobe consolidation.



**Figure 3**  
**Bronchoalveolar lavage fluid cytology showing lipid laden macrophages.**

In view of lipid laden macrophages in BAL and TBLB, we reviewed the history. He recollected that he had aspirated a mineral oil (diesel) during siphoning it from a container, two days prior to onset of illness. So, the diagnosis of exogenous lipoid pneumonia was made. We continued antibiotics and systemic corticosteroids were added in the dose equivalent to 1 mg/kg body weight of prednisolone (initially IV hydrocortisone 300 mg/day and later oral prednisolone 60 mg/day). With this treatment patient's general condition improved. Patient was not requiring oxygen supplementation after a week of therapy. As the TLC started decreasing (Figure 4), IV antibiotics were changed to oral formulations. Patient was discharged on 1 mg/kg body weight of prednisolone for 4 weeks which



**Figure 4**  
**Line diagram showing TLC response to corticosteroids.**

later was tapered and stopped over next two weeks on out patient basis. After about 2 months of discharge patient was asymptomatic and chest X-ray showed marked resolution (Figure 1b).

**Discussion**

Lipoid pneumonia is an unusual cause of respiratory symptoms and has been reported in all age groups. Initial reports of LP predominantly included children - often with local anatomic defects like cleft palate or debilitated adults, but several reports indicate that it can occur in healthy individuals as well [6,7]. There are reports of LP associated with aspirating or inhaling mineral oil, oil based laxatives, lip balm, lip glow etc [7,8]. In our country siphoning of various mineral oils (like diesel) from containers is a common practice and may be an important risk factor for LP. Other risk factors described in infants and small children are use of traditional folk remedies like, use of oily nasal drops, forceful animal fats feeding, such as "ghee", to establish regular bowel habits or transnasal use to treat cough and cold [9,10].

The usual presentation of LP is an insidious onset of dyspnea and/or cough, similar to those of many other chronic lung diseases. Less commonly described clinical features include chest pain, hemoptysis, and intermittent fever [11]. Physical examination findings may be unremarkable or there may be dullness on percussion, crackles, wheezes or rhonchi. Acute presentation simulating infectious pneumonia with fever, with or without cough is unusual [11]. Our patient presented with acute illness with clinical and radiological features consistent with community acquired pneumonia. Blood gas parameters were consistent with acute lung injury (ALI). This is uncommon presentation of LP. However, acute presentation with respiratory failure is reported with accidental/suicidal massive exposure to mineral oil but not with sub-massive exposure or inhalation [2,3,12].

Laboratory tests are usually normal. However, there may be leukocytosis and an increased erythrocyte sedimentation rate. Radiological findings are diverse and may mimic carcinoma, acute or chronic pneumonia, ARDS, or a localized granuloma [13]. CT scan and magnetic resonance imaging can detect fat within pulmonary tissue. The most commonly described feature is alveolar consolidations of low attenuation values, ground glass opacities with thickening of intralobular septa (crazy paving pattern), or alveolar nodules [13,14]. Pathologically, it is characterized by giant cell granulomatous reaction (hence also called lipid granulomatosis), chronic inflammation, and alveolar and interstitial fibrosis [13]. Diagnosis of LP depends on detecting fat-laden macrophages in sputum, bronchoscopic alveolar lavage (BAL), fine needle aspiration cytology (FNAC) or biopsy from the lung lesion [4,5].

Treatment of LP is not well studied and experiences are only with case reports. Avoiding ongoing exposure and providing supportive care is the main stay of treatment. There are anecdotal reports of systemic corticosteroids use to slow the inflammatory response [15]. However, corticosteroids may not be used routinely and may be used if the lung injury is severe and ongoing. Our case presented with acute lung injury and responded well to corticosteroids. Some authors have described resection of nodules and masses in these cases [9].

Lipoid pneumonia is usually indolent however it may be progressive also. Risk factors for progressive disease are concurrent debilitating illness and continued exposure to mineral oil [7]. Therefore, early diagnosis and avoidance exposure to fatty substances is the most important step to avoid long term sequelae.

### Conclusion

Acute presentation of LP simulating acute CAP with ALI is uncommon. Diagnosis may be delayed like our case where LP was not considered in differential diagnosis until FOB was performed. Therefore, physicians should be aware of this disease which can present acute as well as chronic respiratory illness. Once diagnosed, it may require prolonged corticosteroids for treatment.

### Abbreviations

BAL: bronchoalveolar lavage; FOB: fiberoptic bronchoscopy; IV: intravenous; LP: lipoid pneumonia; TBLB: trans-bronchial lung biopsy; TLC: total leukocyte count.

### Consent

Written informed consent was obtained from the patient for publication of this case report and accompanying images. A copy of the written consent is available for review by the Editor-in-Chief of this journal.

### Competing interests

The authors declare that they have no competing interests.

### Authors' contributions

VH and GCK were involved in the patient care, acquisition of data, analysis and interpretation of data, review of literature, drafting and revising the manuscript. ASB and SM were involved in reporting of radiological and pathological investigations, respectively. All authors read and approved the final manuscript.

### References

- Adams FD, Pittman H: **Lipid pneumonia of right middle lobe.** *N Engl J Med* 1949, **241(15)**:579-582.
- Facon D, Coumbaras J, Bigot E, Bahlouli F, Boissonnas A, Bellin MF: **Acute hydrocarbon pneumonia after white spirit aspiration: sequential HRCT findings.** *Eur Radiol* 2005, **15(1)**:31-33.
- Aibar Arregui MA, Laborda Ezquerro K, Conget Lopez F: **Lipoid pneumonia related to an accidental aspiration of gas-oil.** *An Med Interna* 2007, **24(4)**:187-189.
- Levade T, Salvayre R, Dongay G, Dang QQ, Vieu C, Bessac A, Douste-Blazy L: **Chemical analysis of the bronchoalveolar washing fluid in the diagnosis of liquid paraffin pneumonia.** *J Clin Chem Clin Biochem* 1987, **25(1)**:45-48.
- Ferretti GR, Jankowski A, Rodiere M, Brichon PY, Brambilla C, Lantuejoul S: **CT-guided biopsy of nonresolving focal air space consolidation.** *J Thorac Imaging* 2008, **23(1)**:7-12.
- Meltzer E, Guranda L, Perelman M, Krupsky M, Vassilenko L, Sidi Y: **Lipoid pneumonia: a preventable form of drug-induced lung injury.** *Eur J Intern Med* 2005, **16(8)**:615-617.
- Gondouin A, Manzoni P, Ranfaing E, Brun J, Cadraner J, Sadoun D, Cordier JF, Depierre A, Dalphin JC: **Exogenous lipid pneumonia: a retrospective multicentre study of 44 cases in France.** *Eur Respir J* 1996, **9(7)**:1463-1469.
- Salm R, Hughes EW: **A case of chronic paraffin pneumonitis.** *Thorax* 1970, **25(6)**:762-768.
- Annobil SH, Benjamin B, Kameswaran M, Khan AR: **Lipoid pneumonia in children following aspiration of animal fat (ghee).** *Ann Trop Paediatr* 1991, **11(1)**:87-94.
- Hugosson CO, Riff EJ, Moore CC, Akhtar M, Tufenkeji HT: **Lipoid pneumonia in infants: a radiological-pathological study.** *Pediatr Radiol* 1991, **21(3)**:193-197.
- Fournier P, Aerts J, Damade R, Pasquier P: **A rare cause of inflammatory syndrome: lipoid pneumonia.** *Presse Med* 1990, **19(38)**:1768-1769.
- Bernabeu Mora R, Mendez Martinez P, Abellan Martinez MC, Polo Garcia LA, Lorenzo Cruz M, Sanchez Gascon F: **Acute lipoid pneumonia caused by accidental aspiration of vaseline used in nasogastric intubation.** *Arch Bronconeumol* 2000, **36(8)**:485-487.
- Laurent F, Philippe JC, Vergier B, Granger-Veron B, Darpeix B, Vergeret J, Blanc P, Velly JF: **Exogenous lipoid pneumonia: HRCT, MR, and pathologic findings.** *Eur Radiol* 1999, **9(6)**:1190-1196.
- Baron SE, Haramati LB, Rivera VT: **Radiological and clinical findings in acute and chronic exogenous lipoid pneumonia.** *J Thorac Imaging* 2003, **18(4)**:217-224.
- Chin NK, Hui KP, Sinniah R, Chan TB: **Idiopathic lipoid pneumonia in an adult treated with prednisolone.** *Chest* 1994, **105(3)**:956-957.

Publish with **BioMed Central** and every scientist can read your work free of charge

"BioMed Central will be the most significant development for disseminating the results of biomedical research in our lifetime."

Sir Paul Nurse, Cancer Research UK

Your research papers will be:

- available free of charge to the entire biomedical community
- peer reviewed and published immediately upon acceptance
- cited in PubMed and archived on PubMed Central
- yours — you keep the copyright

Submit your manuscript here:  
[http://www.biomedcentral.com/info/publishing\\_adv.asp](http://www.biomedcentral.com/info/publishing_adv.asp)

