



Case report

## Treatment of neonatal septic arthritis sequelae of hip: a case report

Cen Bytyçi<sup>1\*</sup>, Hasime Qorraj<sup>1</sup> and Dafina Bytyqi<sup>2</sup>

Addresses: <sup>1</sup>Orthopaedic Department, University Clinical Center, Prishtina, Kosovo and <sup>2</sup>Faculty of Medicine, University of Prishtina, Prishtina, Kosovo

Email: CB\* - cenbytyqi@yahoo.com; HQ - hqorraj@hotmail.com; DB - dafinabytyqi@gmail.com

\* Corresponding author

Received: 3 March 2009 Accepted: 11 June 2009 Published: 1 July 2009

Cases Journal 2009, 2:6332 doi: 10.4076/1757-1626-2-6332

This article is available from: <http://casesjournal.com/casesjournal/article/view/6332>

© 2009 Bytyçi et al; licensee Cases Network Ltd.

This is an Open Access article distributed under the terms of the Creative Commons Attribution License (<http://creativecommons.org/licenses/by/3.0>), which permits unrestricted use, distribution, and reproduction in any medium, provided the original work is properly cited.

### Abstract

**Introduction:** The most serious complication of the septic arthritis of the hip in childhood and especially in newborns is the avascular necrosis of the femoral head. The aim of the study was evaluation of residual deformity after neonatal septic arthritis of the hip in a boy aged thirteen years.

**Case presentation:** A 13-year-old, white male, was operatively treated by intertrochanteric osteotomy of valgisation, anterotation and extension at age of twelve years because of leg length discrepancy, changes in the femoral neck, coxa vara, plana and breva. It was delay in diagnosis and failure to begin treatment promptly in the neonatal period.

**Conclusion:** Valgus intertrochanteric osteotomy of the femur, moves the greater trochanter distally and laterally, tensioning the abductors muscles and improving their leverage.

### Introduction

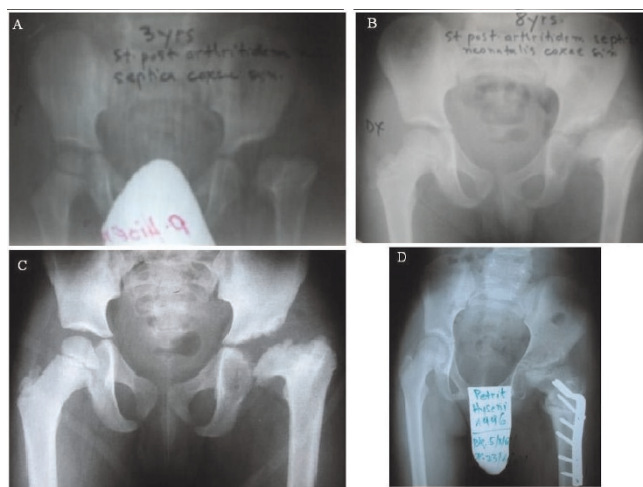
The most serious complication of the septic arthritis of the hip in childhood and especially in newborns is the avascular necrosis of the femoral head, which can lead to partial or complete destruction of the capital femoral epiphysis, the growth plate or both [1]. The aim of the treatment of sequelae of neonatal septic arthritis of the hip is to preserve good relation between the femoral head and acetabulum.

### Case presentation

We present a case of a 13-year-old boy, complaining of painless limp on the left hip. He had suffered septic arthritis of the left hip in the neonatal period. At follow-up from 3 to 13 years, a trend towards severe deformities was seen (Figure 1 A, B). On clinical examination, there was

muscle wasting at the left hip and thigh region. The patient had Duchenne-Trendelenburg limp and the Trendelenburg sign with flexion, rotational and adduction contracture of the left hip. Abduction and adduction was tested with patient supine.

The Thomas test was positive and flexion deformity was 25°, abduction 20°, adduction deformity of 25°. Internal and external rotation was determined with the patient prone. Internal rotation was limited of 20°. Determination of leg length discrepancy was done with patient laying and standing, and the shortening was 3.8 cm. Magnetic Resonance Imaging (MRI) was not done because our hospital lacks the equipments. According to the system suggested by Choi et al [2] our patient was grouped under Choi's Type IIIA, (Figure 1C) with severe coxa vara angular



**Figure 1.** Late metaphyseal changes in the femoral neck, coxa vara, plana and brevis associated with septic arthritis of the hip. **(A)** Three years after the onset of septic arthritis on the left hip. **(B)** Sequelae of acute septic arthritis of the hip at the age of eight. **(C)** Ten-year-old, the result before an abduction intertrochanteric osteotomy. **(D)** Twelve years old, the result after an abduction intertrochanteric osteotomy.

deformity with retroversion but no pseudoarthrosis of the femoral neck. Intertrochanteric osteotomy was done at the age of twelve with lateral approach to change the loading of the hip and to place the epiphyseal plate at right angle to the resultant of the compressive forces. With this intertrochanteric osteotomy of valgisation of 35° with anterototation of 10° and extension 25° we achieved transferring the greater trochanter distally and laterally so it is level with the center of the femoral head, restoring normal tension to the pelvitrochanteric muscles and improving their mechanical efficiency (Fig.1 D). With this procedure, we placed the superior end of the femur against the lateral aspect of the pelvis and also increased the distance between the tip of the trochanter and the center of the hip rotation.

## Conclusion

Delay in diagnosis, failure to begin treatment promptly, and patient age less than 1 year are the most common reason for late complication [3-6]. Acute septic arthritis represent surgical emergency, which demands early and vigorous treatment in order to preserve normal joint function [7,8]. In our case, intertrochanteric femoral osteotomy increased the stability of the hip due to correction of the neck-shaft angle. In this type of osteotomy the operation is extracapsular so the hip joint is not directly approached. The intertrochanteric osteotomy in our case has given a satisfactory result, improving the lower-extremity length discrepancy from 3.8 cm

preoperatively to 1.2 cm postoperatively. The pelvic drop (Trendelenburg gait) was also reduced.

## Abbreviations

MRI, Magnetic Resonance Imaging.

## Consent

Written informed consent was obtained from the patient for publication of this case report and accompanying images. A copy of the written consent is available for review by the Editor-in-Chief of this journal.

## Competing interests

The authors declare that they have no competing interests.

## Authors' contributions

CB admits the patient in the hospital, definite the diagnosis, followed - up the case and performed the operation. HQ detected the disease and was a major contributor in writing the manuscript. All authors read and approved the final manuscript.

## Acknowledgements

DB contributed in drafting the manuscript.

## References

1. Rozbruch SR, Paley D, Bhav A, Herzenberg JE: **Ilizarov Hip reconstruction for late sequelae of infantile hip.** *J Bone Joint Surg Am* 2005:1007-1018.
2. Choi IH: **Sequelae and reconstruction after septic arthritis of the hip in infants.** *J Bone Joint Surg Am* 1990, **72**:1150.
3. Kocher MS, Mandiga R, Zurakowski D, Barnewolt C, Kasser JR: **Validation of a clinical prediction rule for the differentiation between septic arthritis and transient synovitis of the hip in children.** *J Bone Joint Surg Am* 2004, **86**:1629-1635.
4. Goldenberge DL, Reed JI: **Bacterial arthritis.** *N Engl J Med* 1985, **312**:764-771.
5. Bonhoeffer J, Haeberle B, Shaad U, Heining U: **Diagnosis of acute haematogenous osteomyelitis and septic arthritis: 20 years experience at the University children's hospital Basel.** *Swiss Med Wkly* 2001, **131**:575-581.
6. Vidigal EC, Jacomo AD: **Early diagnosis of septic arthritis of the hip in neonates.** *Int Orthop* 1994, **18**:189-192.
7. Eich GF, Superi-Furga A, Umbricht FS, Willi UV: **The painful hip: evaluation of criteria for clinical decision -making.** *Eur J Pediatr* 1999, **158**:923-928.
8. McCarthy JJ, Dormans JP, Kozin SH, Pizzullo PD: **Musculoskeletal infections in children. Basic treatment principles and recent advancements.** *J Bone Joint Surg Am* 2004, **86**:850-863.