



Case report

Closed posteromedial dislocation of ankle in a 12 year-old boy: a case report

Yüksel Yurttaş¹, Volkan Kiliçoğlu², Serdar Toker^{2*}, Mustafa Kürklü¹,
Atıl Atilla³ and Mustafa Başbozkurt³

Addresses: ¹Department of Orthopaedics and Traumatology, Gulhane Military School of Medicine, General Dr. Tevfik Sağlam Cad.Etilik/Ankara, Turkey

²Department of Orthopaedics and Traumatology, Dumlupinar University School of Medicine, Tavsanlı yolu 10.km.43270, Kutahya, Turkey

³Gulhane Military School of Medicine, General Dr. Tevfik Sağlam Cad.Etilik/Ankara, Turkey

Email: YY - yyurttas@hotmail.com & mkurklu@yahoo.com; VK - v.kilincoglu@hotmail.com; ST* - tokerserdar@hotmail.com; MK - mkurklu@yahoo.com; AA - atilatilla@gmail.com; MB - mbasbozkurt@hotmail.com

* Corresponding author

Received: 13 March 2009 Accepted: 12 June 2009 Published: 17 July 2009

Cases Journal 2009, **2**:6550 doi: 10.4076/1757-1626-2-6550

This article is available from: <http://casesjournal.com/casesjournal/article/view/6550>

© 2009 Yurttaş et al; licensee Cases Network Ltd.

This is an Open Access article distributed under the terms of the Creative Commons Attribution License (<http://creativecommons.org/licenses/by/3.0>), which permits unrestricted use, distribution, and reproduction in any medium, provided the original work is properly cited.

Abstract

Ankle fractures and fracture dislocations are common injuries in orthopaedic practice however pure ankle dislocation without an associated fracture is extremely rare. There are a few cases reporting such a lesion in the literature. Also this injuries are generally open high energy trauma injuries. Closed treatments are reported to be effective and ligament injuries are generally not reported. In this study, we report a closed pure posteromedial ankle dislocation with anterior talofibular ligament rupture and its treatment and outcome in a 12 year-old boy. We think that this is an extremely rare lesion.

Introduction

Pure dislocation (dislocation without associated fractures) of the posterior border of the tibia is an extremely rare injury [1-5]. The rarity is due to mechanical efficacy of the ankle mortise and resistance of the ankle ligaments being greater than bone making fracture common [6]. Sporadic cases [7-10] and a few series with a limited number of adult patients have been published [11-17]. Among skeletally mature patients, open injuries are reported to be more frequent however only a few patients with posterior dislocation and entrapment of the entire distal part of the fibula behind the tibia without associated fracture has been reported in the pediatric age group [18]. In this case report, we present one of these rare injuries; a closed true

posteromedial dislocation of the ankle without associated fracture of the ankle region in a 12 year-old boy and its treatment with closed reduction and below-knee casting.

Case presentation

A 12 year-old Turkish boy from Turkey, referred to emergency room following right ankle injury while running. In initial examination, the ankle swelling and deformity drew attention. The hindfoot seemed to be displaced posterior to the ankle (Figure 1). There were no signs of injury to the neurovascular structures. Ankle X-ray revealed frank posteromedial dislocation of the talus without associated fracture (Figures 2, 3). Following 50 mg diazepam administration intermuscularly, closed reduction was performed by

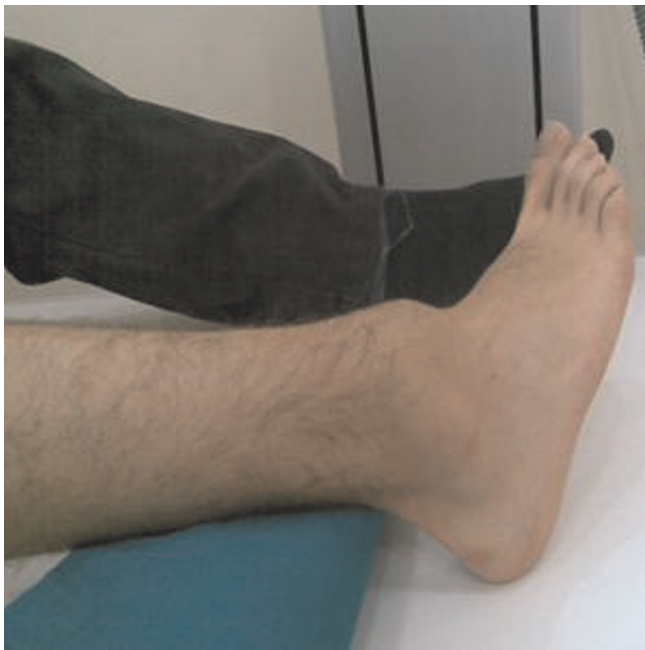

Figure 1. The photograph of the ankle in the emergency room showing posterior dislocation.

longitudinal traction with one hand on the heel and the other on the forefoot and the limb was placed in a short leg cast. Control X-ray revealed a normal tibio-talar alignment (Figure 4). Magnetic resonance imaging (MRI) revealed an

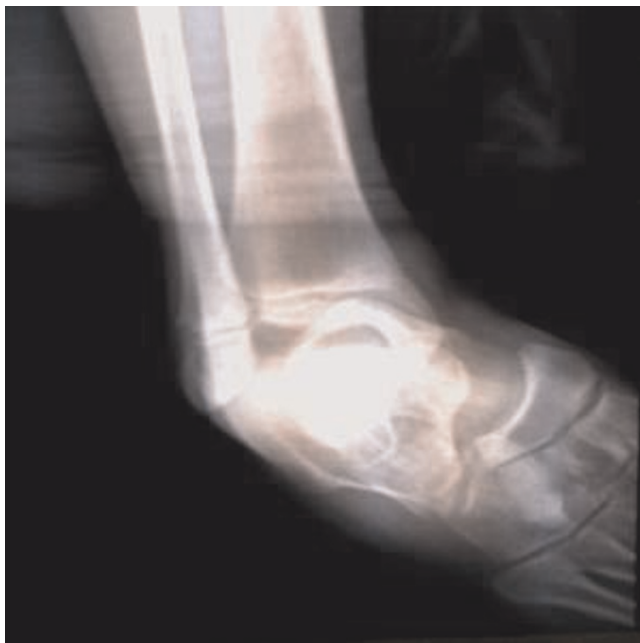

Figure 2. AP X-ray graphy of the ankle representing medial dislocation.

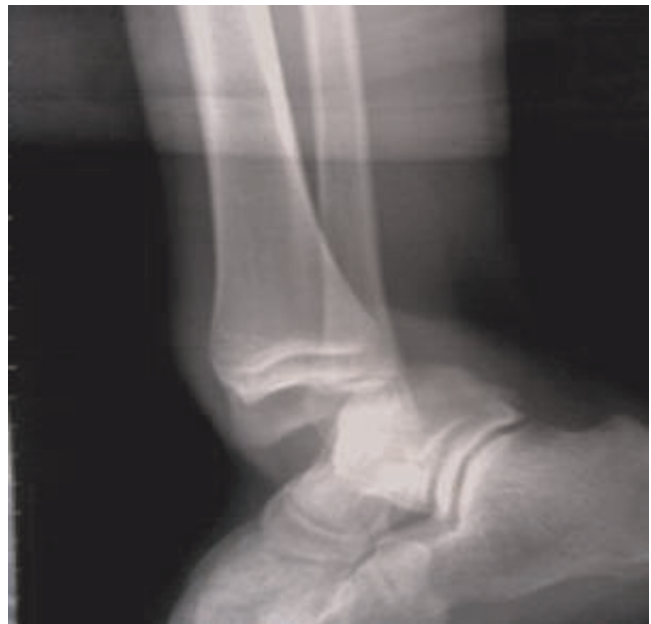


Figure 3. Lateral X-ray ankle showing posterior dislocation.

anterior talofibular ligament rupture (Figure 5). The patient was interned, and the extremity was elevated. Following pain relief and decrease in swelling and oedema, the patient was allowed to ambulate without weight-bearing using crutches. Weight-bearing was not allowed for a total of 4 weeks. He was instructed to elevate his leg, take NSAIDS, use ice and crutches in a non-weight bearing manner until further evaluation. Follow-up examination at one-month post injury

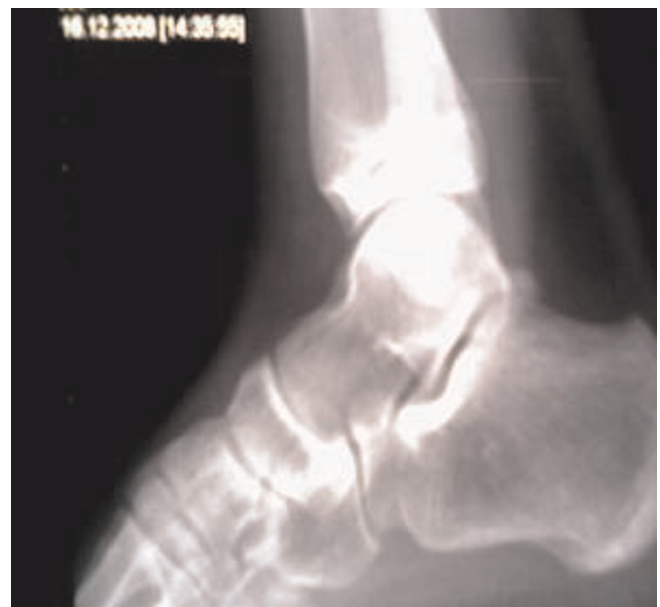

Figure 4. Lateral X-ray of the ankle after reduction.

indicated moderate swelling with good range of motion and a congruent reduction. No instability was detected. At this time, he was advised to begin physical therapy and progressively apply weight over the next few weeks, and was cleared to return to activity seven weeks post-injury.

Discussion

Ankle fractures and fracture dislocations are common injuries in orthopaedic practice however pure ankle dislocation without an associated fracture is extremely rare [3,5,19]. The rarity is described to be due to mechanical efficacy of the ankle mortise and resistance of the ankle ligaments being greater than bone making fracture common [6]. Moehring et al reported a series of 14 patients with pure ankle dislocation who all were young adults (18-41 years of age) and mostly experienced a high-energy trauma with an open fracture in thirteen of the 14 injuries [2]. Rivera et al also reported a series of three cases with pure ankle dislocation of which one was closed posterior dislocation while two others were open dislocations with one posteromedial dislocation [3]. One can suggest that, pure ankle dislocations are rare injuries but pure, closed ankle dislocations are unique and such injuries mostly need to have high energy trauma, like traffic accident or fall from height [6]. In our case, we report a pure, closed posteromedial ankle dislocation produced by a low-energy trauma so we think that, despite the most common ankle dislocation is reported to be posteromedial dislocation, this case may be one of the unique cases among the others.

The mechanism of pure tibiotalar dislocation is thought to be occurred with maximal plantar flexion followed by

inversion. In our case, the mechanism of injury also appeared to be plantarflexion and inversion.

Predisposing factors that contribute to the pathogenesis of this lesion are internal malleolus hypoplasia, ligamentous laxity, weakness of the peroneal muscles, and previous ankle sprains [3]. Our patient had neither history of previous ankle sprain nor an evidence of ligamentous laxity or a muscle weakness in the physical examination. 'For evaluating the medial malleolus hypoplasia, the ratio between the length of the medial (B) and lateral (A) malleolus was evaluated by the method of Elisé et al. [20] in anteroposterior ankle radiograph and it was found to be in normal ranges (eg:0.62) (Figure 6).'

In posteromedial ankle dislocations, associated injuries to the anterolateral neurovascular structures have been reported [1-15,16] however any instability detected after closed reduction in most of the cases [2]. In our case, no neurovascular injury was present but in MRI study, we found anterior talofibular ligament rupture that we could not find a case in the literature reporting this lesion with pure posteromedial ankle dislocation so it may be important to point out that MRI study and clinical reexamination must be performed after reduction of a posteromedial ankle dislocation not only for a neurovascular injury but also for an anterior talofibular ligament lesion.

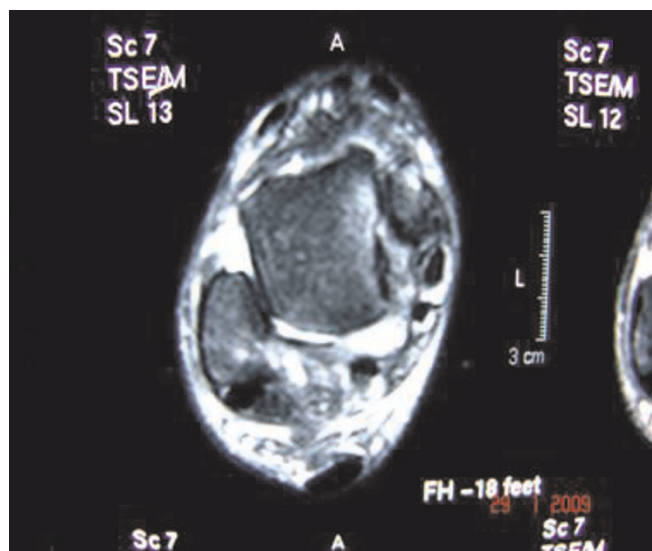


Figure 5. Magnetic resonance imaging showing anterior cruciate ligament rupture.

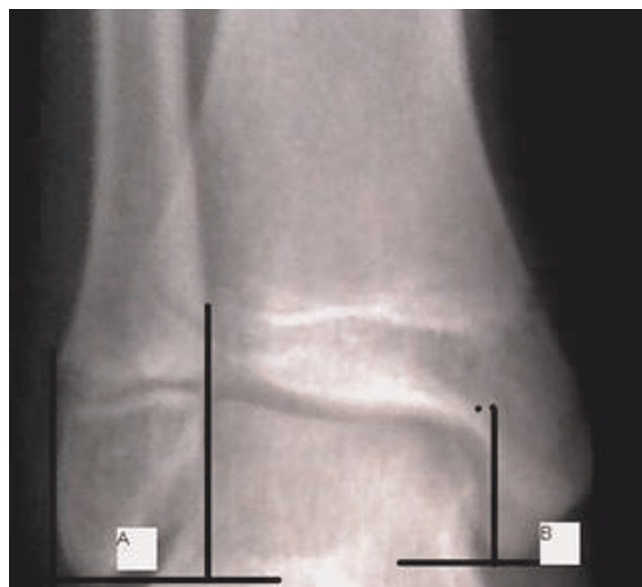


Figure 6. For evaluating the medial malleolus hypoplasia, the ratio between the length of the medial (B) and lateral (A) malleolus evaluated by the method of Elisé et al. [20] in anteroposterior ankle radiograph and it was found to be in normal ranges (0.62).

It is a general agreement that the majority of pure closed ankle dislocations can be treated by closed reduction and cast immobilization. Conservative and operative treatments have been applied to this unusual injury. In closed dislocation, if good reduction is achieved, no operative repairs have been necessary. Wroble et al. stated that closed reduction can be performed easily and optimum treatment is immobilization in a short leg cast for 6 weeks with no weight bearing for the first 3 weeks, following closed reduction [5]. In open dislocation, management consists of immediate reduction followed by debridement and capsular suture and immobilization with a short leg cast [3]. Moehring et al. reported that 12 of 13 patients with open dislocations underwent lateral ligamentous repair [2]. In the present case, we could achieve closed reduction under a mild sedation easily and we applied short leg cast for 4 weeks without weight-bearing. At the end of four weeks, no instability was detected. At this time, he was advised to begin physical therapy and progressively apply weight over the next few weeks, and was cleared to return to activity seven weeks post-injury.

Conclusions

Closed posteromedial ankle dislocation without an associated fracture is extremely uncommon. Care must be taken for neurovascular injury especially to the anterolateral neurovascular structures but anterior talofibular ligament lesion must also be kept in mind so MRI study, after reduction, can be useful. Closed reduction under sedation is a recommended treatment and prognosis is good. 4-6 weeks of immobilization is generally enough to achieve a stable ankle.

Abbreviations

NSAID, non-steroid antienflammatory drugs; MRI, magnetic resonance imaging; AP, Anteroposterior.

Consent

Written informed consent was obtained from the patient for publication of this case report and accompanying images. A copy of the written consent is available for review by the Editor-in-Chief of this journal.

Competing interests

The authors declare that they have no competing interests.

Authors' contributions

YY analyzed and interpreted the patient data. VK, and ST was the major contributor in writing. MK helped in searching the literature. AA involved in treatment management. MB involved in checking all the course.

References

- Colville M, Colville J, Manoli A: **Posteromedial dislocation of the ankle without fracture.** *J Bone Joint Surg Am* 1987, **69**:706-711.
- Moehring HD, Tan RT, Marder RA, Lian G: **Ankle dislocation.** *J Orthop Trauma* 1994, **8**:167-172.
- Rivera F, Bertone C, De Martino M, Pietrobono D, Ghisellini F: **Pure dislocation of the ankle: three case reports and literature review.** *Clin Orthop Rel Res* 2001, **382**:179-184.
- Tranovich M: **Ankle Dislocation without Fracture.** *The Physician and Sportsmedicine* 2003, **31**:42-45.
- Wroble R, Nepola J, Malvitz T: **Ankle dislocation without fracture.** *Foot Ankle* 1988, **9**:64-74.
- D'Anca A: **Lateral rotatory dislocation of the ankle without fracture.** *J Bone Joint Surg* 1970, **52**:A1643-A1646.
- Daruwalla JS: **Medial dislocation of the ankle without fracture: a case report.** *Injury* 1974, **5**:215-216.
- Krishnamurthy S, Schultz RJ: **Pure posteromedial dislocation of the ankle joint.** *Clin Orthop* 1985, **201**:68-70.
- Mooney JF, Naylor PT, Poehling GG: **Anterolateral ankle dislocation without fracture.** *South Med J* 1991, **84**:244-247.
- Rasmussen O: **Stability of the ankle joint: analysis of the function and traumatology of the ankle ligaments.** *Acta Orthop Scand Suppl* 1985, **211**:1-75.
- Fahey JJ, Mutphy JL: **Dislocations and fractures of the talus.** *Surg Clin North Am* 1962, **45**:79-102.
- Kelly PJ, Peterson LFA: **Compound complete dislocation of the ankle joint without fracture.** *Am J Surg* 1962, **103**:170-172.
- Olerud S: **Subluxation of the ankle without fracture of the fibula.** *J Bone Joint Surg Am* 1971, **53**:594-596.
- Scott JE: **Dislocation of the ankle without fracture.** *Br J Accid Surg* 1974, **6**:63-66.
- Toohey JS, Worsing RA: **A long-term follow-up study of tibiotalar dislocations without associated fractures.** *Clin Orthop* 1989, **239**:207-210.
- Wehner J, Lorenz M: **Lateral ankle dislocation without fracture.** *J Orthop Trauma* 1990, **4**:362-366.
- Wilson AB, Toriello EA: **Lateral rotatory dislocation of the ankle without fracture.** *J Orthop Trauma* 1991, **5**:93-95.
- Lovell ES: **An unusual rotatory injury of the ankle.** *J Bone Joint Surg Am* 1968, **50**:163-165.
- Demiralp B, Komurcu M, Ozturk C, Ozturan K, Tasatan E, Erler K: **Acute traumatic open posterolateral dislocation of the ankle without tearing of the tibiofibular syndesmosis ligaments: a case report.** *J Am Podiatr Med Assoc* 2008, **98**:469-472.
- Elisé S, Maynou C, Mestdagh H, Forgeois P, Labourdette P: **Simple tibiotalar luxation. Apropos of 16 cases.** *Acta Orthop Belg* 1998, **64**:25-34.

Do you have a case to share?

Submit your case report today

- Rapid peer review
- Fast publication
- PubMed indexing
- Inclusion in Cases Database

Any patient, any case, can teach us something



**CASES
NETWORK**

www.casesnetwork.com