



Case report

## Expanding spectrum of illness due to community-associated methicillin-resistant *Staphylococcus aureus*: a case report

Russell Kempker<sup>1\*</sup>, Lorenzo Difrancesco<sup>2</sup>, Alejandro Martin-Gorgojo<sup>3</sup>  
and Carlos Franco-Paredes<sup>1</sup>

Addresses: <sup>1</sup>Department of Infectious Diseases, Emory University School of Medicine, 550 Peachtree Street, MOT 7<sup>th</sup> Floor Atlanta, GA 30308, USA

<sup>2</sup>Department of General Medicine, Emory University School of Medicine 69 Jesse Hill Jr, Drive, S.E. Atlanta, GA 30303, USA

<sup>3</sup>University of Valencia Medical School, Avda Blasco Ibanez 15, Valencia 460101, Spain

Email: RK\* - rkempke@emory.edu; LD - ldifran@emory.edu; AMG - margora@alumni.uv.es; CFP - cfranco@emory.edu

\* Corresponding author

Received: 23 April 2009 Accepted: 29 July 2009 Published: 17 August 2009

Cases Journal 2009, 2:7437 doi: 10.4076/1757-1626-2-7437

This article is available from: <http://casesjournal.com/casesjournal/article/view/7437>

© 2009 Kempker et al.; licensee Cases Network Ltd.

This is an Open Access article distributed under the terms of the Creative Commons Attribution License (<http://creativecommons.org/licenses/by/3.0>), which permits unrestricted use, distribution, and reproduction in any medium, provided the original work is properly cited.

### Abstract

**Introduction:** Xanthogranulomatous pyelonephritis is a rarely identified form of chronic pyelonephritis usually caused by gram-negative organisms. Herein, we report the first case caused by infection due to community-associated methicillin-resistant *Staphylococcus aureus* strain.

**Case presentation:** An HIV-infected female with a history of intravenous drug use presented with a three month history of abdominal pain, distension, and fever. Computerized tomography of the abdomen revealed a large multicystic right kidney mass. During surgical exploration an intrarenal abscess was identified. Cultures revealed the presence of community-associated methicillin-resistant *Staphylococcus aureus*. Histopathological examination demonstrated xanthogranulomatous disease. The patient was successfully treated with nephrectomy and a prolonged antibiotic combination regimen with vancomycin and linezolid.

**Conclusion:** Our case illustrates the escalating spectrum of illness caused by infection due to community-associated methicillin-resistant *Staphylococcus aureus*.

### Introduction

Infection with methicillin-resistant *Staphylococcus aureus* (MRSA) was first reported in the early 1960s, shortly after the introduction of methicillin and evolved into an important cause of nosocomial infection. Over the last three decades the incidence of MRSA infection in the United States and worldwide has dramatically increased [1]. The rise in MRSA infections has become an economic burden on the US health care system and is responsible

for increasing amounts of patient morbidity and mortality. In a recent study by Klevens et al, it was estimated that 94,360 cases of invasive MRSA infection associated with death in 18,650 cases occurred in the United States in 2005 [2]. Reports have also shown MRSA infections to cause increased rates of morbidity and mortality as compared to methicillin sensitive *Staphylococcus aureus* infections [3,4]. More recently MRSA infection has begun to emerge in the community setting, with some cases

occurring in patients who have never been hospitalized and who have no risk factors for MRSA infection. These cases have been defined as community-associated (CA) MRSA infections [5].

Strains of MRSA causing epidemiologically defined community associated and health care associated (HA) MRSA disease have been shown to be distinct. In a study comparing CA and HA MRSA infection it was shown that isolates from the community were more susceptible to non-B Lactam antibiotics, and more likely to possess *staphylococcal chromosomal cassette mec IV* and contain genes encoding for Panton-Valentine leukocidin (PVL) toxin [6]. Molecular typing studies with pulse field gel electrophoresis have defined one pulsed-field type that accounts for most CA MRSA disease, specified as type USA 300. In addition CA MRSA infections also tend to be found more often among healthy, community dwelling persons without traditional risk factors for MRSA [7].

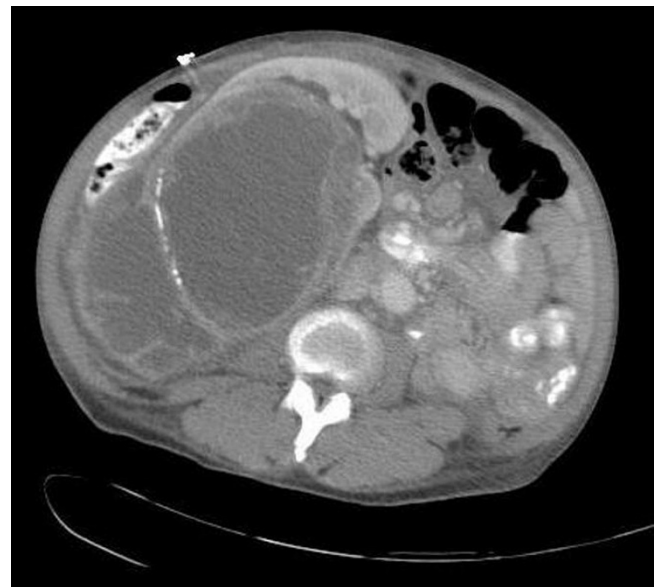
The rapid evolution of CA MRSA infections has taken place over the last decade and a half. In 1993, MRSA infections among western Australian aborigines with no health care exposure were reported [8]. In 1999, four cases of rapidly fatal CA MRSA infections in children from the United States were described [9]. These reports heralded the rising epidemic of CA MRSA infections. In a recent population based surveillance study of three communities in 2001-2002 the CDC found between 8-20% of all MRSA infections were caused by CA MRSA and an annual disease incidence as high as 25.7/100,000 persons in the general population of Atlanta [10]. In analysis of all community onset skin and soft tissue infections presenting to a county hospital emergency room in Atlanta, King et al. found that CA MRSA caused approximately two-thirds of the cases [11]. While the majority of CA MRSA infections are skin and soft tissue infections, CAMRSA may also cause severe invasive disease [2,6]. Reports of CAMRSA causing life threatening infections include cases of necrotizing pneumonia and necrotizing fasciitis [12,13]. Other emerging clinical syndromes associated with CA MRSA include Waterhouse-Friderichsen syndrome, empyema, septic thrombophlebitis, prostatic abscess, and bacteremia [14]. In a large case series of CA MRSA infections, urinary tract infections have been reported to cause up to 4% of CA MRSA infections but none of these cases led to xanthogranulomatous pyelonephritis (XGP) [10]. This condition is typically caused by enteric gram-negative bacilli most commonly *Proteus mirabilis* or *Escherichia coli*. The pathogenesis of XGP is believed to involve a combination of nephrolithiasis, obstruction, and ascending infection [15]. We were therefore interested in reporting a case of XGP associated with CA MRSA in an HIV-infected patient.

### Case presentation

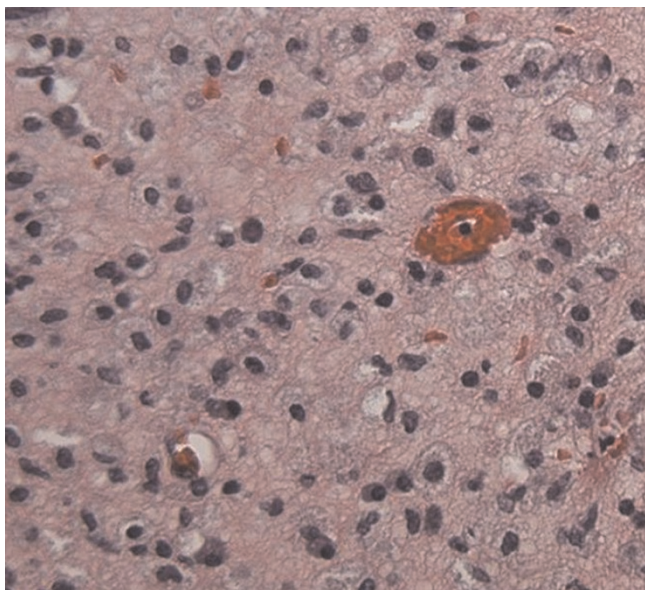
A 52-year-old African American HIV infected female presented with three months of progressive abdominal pain, distension, and fever. The patient had never been on antiretroviral therapy and had a CD4 T-cell count of 396 cells/ $\mu$ L at the time of admission with an unknown HIV RNA viral load. She had a history of discoid lupus, hepatitis C, active tobacco, alcohol, and intravenous drug use (IVDU). The patient had not been hospitalized or seen in outpatient clinics in the previous year, and was not taking any medications. She reported living with a family member and denied any sick contacts.

On examination, the patient was found to be febrile at 39.6°C. Physical examination was remarkable for a distended abdomen with right-sided costo-vertebral tenderness and right lower extremity track marks. On laboratory analysis, the leukocyte count was 9240/mcl with 71% segmented neutrophils, the hemoglobin 8.3 gm/dl, creatinine 1.2 mg/dl, and albumin 1.9 gm/dl. The rest of the chemistry panel including amylase and lipase were within normal. The urinalysis revealed 5-10 RBC/hpf with no WBC's, a negative HCG pregnancy test, and a drug screen positive for cocaine and opiates.

The patient was admitted to the hospital for further work up. A computed tomography (CT) scan of the abdomen and pelvis was done which revealed a 17.5 cm \* 12.8 cm multicystic right-sided renal mass with septations and no evidence of invasion (Figure 1). The initial diagnostic



**Figure 1.** Abdominal CT scan revealing a large, complex cystic mass with multiple enhancing septations and septae calcifications arising from the right kidney.



**Figure 2.** Histopathology at 40× magnification reveals characteristic foamy histiocytes as well as scattered plasma cells and lymphocytes and the absence of any normal renal tissue.

impression was consistent with a multilocular cystic nephroma. The patient continued to be febrile and was started empirically on vancomycin and piperacillin-tazobactam. Urine and blood cultures sent on admission and multiple repeat blood cultures throughout the hospital stay came back as negative. Two weeks into her hospital stay the patient underwent surgical exploration. A large intrarenal abscess drained over three liters of purulent material and nephrectomy was subsequently performed. Cultures grew out MRSA sensitive to erythromycin, clindamycin, trimethoprim-sulfamethoxazole, levoquin, gentamycin, vancomycin, and linezolid. Based on this antibiogram we concluded that this bacterial isolate was consistent with a CA MRSA strain. Pathologic examination showed significant necrotic tissue, an abundance of inflammatory cells, and foamy histiocytes or xanthoma cells all characteristic of XGP (Figure 2). After surgery, the patient received a three-week course of vancomycin switched to linezolid upon discharge with complete recovery.

## Discussion

Xanthogranulomatous pyelonephritis was first described as a pathological entity in 1916. It is a rare form of chronic pyelonephritis that results in diffuse renal parenchymal obstruction. The disease process is traditionally associated with nephrolithiasis, obstruction, and infection with enteric gram-negative bacilli, typically *Proteus mirabilis* or *Escherichia coli*. It is unclear if the obstruction or the infection is the inciting pathological event [15]. *Staphylococcus aureus* has

rarely been reported as a cause of XGP and to our knowledge there are no previous reports in the literature of CA MRSA causing XGP.

Our patient had evidence of XGP caused by MRSA. The patient's MRSA infection met the CDC epidemiological criteria of CA MRSA, as she had no hospital exposure or medical procedures such as surgery, dialysis, or catheter placement during the last year [5]. CA MRSA has also been shown to be microbiology distinct from health care associated MRSA infection. In a study by Naimi et al, comparing the antimicrobial susceptibility pattern of CA MRSA and HA MRSA infections it was found that susceptibility to four non-beta Lactam antibiotics was able to predict a CA MRSA strain with an odds ratio of 2.44 (95% CI, 1.35-3.86) [6]. Our patient's strain of MRSA met this microbiological criterion for CA MRSA.

In 1971, Povsil and colleagues were able to experimentally induce XGP in rats by ligating their ureters and injecting *Escherichia coli* into their tails [16]. Few experiments to further elucidate the mechanisms of pathogenesis have been done since. In prior case series of XGP, *Staphylococcus aureus* has only rarely been identified as a causative agent, and there has been only one case report of XGP due to MRSA specifically [15,17]. Our patient's main risk factor for infection was her history of intravenous drug use, which has been associated with outbreaks of CA MRSA infection [18]. She presented with the common manifestations of fever and flank pain. We presume her CA MRSA infection derived from a skin source, given her history of IVDU and negative blood and urine cultures upon admission. It is also plausible that she had a prior episode of undetectable bacteremia and seeded her kidney at that time. Abreu et al, recently reported 13 cases of retroperitoneal infections caused by CA MRSA in which all cases had preceding skin infections, negative urine cultures, and only three of the thirteen had positive blood cultures [19]. These findings demonstrate the possibility that retroperitoneal CA MRSA infections can come from the skin.

Typical radiological findings of XGP include multiple fluid filled cavities in the affected kidney with extension of the disease into the perinephric space. As with our case, XGP is often confused with other disorders including renal tuberculosis, pyelonephritis with stones, and renal tumors and is commonly not included in the differential diagnosis [20]. XGP is a pathological entity and thus can only be definitively diagnosed by pathological examination. Our patient's pathology exhibited the classic finding of lipid-laden macrophages mixed with chronic inflammatory signs. It is hypothesized that bacterial infection provokes tissue destruction and liberates pericalyceal and necrotic material, attracting inflammatory cells to the area, including macrophages, which take up and become filled with

lipid debris [15]. Our patient made a complete recovery with the combination of open nephrectomy and a prolonged antibiotic course. Nephrectomy is considered the definitive and curative treatment for XGP with antibiotics serving as adjunctive therapy. There have been a few case reports of successful outcomes with antibiotics alone in focal forms of XGP [15]. In addition there have been reports of good outcomes and shorter hospital stays with laparoscopic nephrectomies compared to open nephrectomies [21].

In summary, the clinical spectrum of CA MRSA infections continues to expand. To our knowledge, this is the first report of a patient that developed XGP caused by CA MRSA infection. While the majority of cases produce skin and soft tissue infections there are increasing reports of new suppurative manifestations of CA MRSA infections. Physicians need to be aware of the variety of CA MRSA infections and keep CA MRSA in the differential when dealing with a potential case of XGP.

### Abbreviations

CA, community-associated; HA, healthcare-associated; IVDU, intravenous drug use; MRSA, methicillin-resistant *Staphylococcus aureus*; XGP, xanthogranulomatous pyelonephritis.

### Consent

Written informed consent could not be obtained because the patient was lost to follow-up. Despite repeated attempts we were unable to contact the patient. Every effort has been made to keep the patient's identity anonymous. We would not expect the patient to object to publication.

### Competing interests

The authors declare that they have no competing interests.

### Authors' contributions

RK was a consultant on the case and wrote the primary manuscript and revisions. LD was the primary physician taking care of the patient and edited the manuscript. AMG was involved in patient care, researched the topic, and read and approved the final manuscript. CFP was involved in patient care and edited the manuscript.

### References

- Deresinski S: **Methicillin-resistant *Staphylococcus aureus*: an evolutionary, epidemiological, and therapeutic odyssey.** *Clin Infect Dis* 2005, **40**:562-573.
- Klevens RM, Morrison MA, Nadle J, Petit S, Gershman K, Ray S, Harrison LH, Lynfield R, Dumyati G, Townes JM, Craig AS, Zell ER, Fosheim GE, McDougal LK, Carey RB, Fridkin SK: **Invasive Methicillin-resistant *Staphylococcus aureus* Infections in the United States.** *JAMA* 2007, **298**:1763-1771.
- Shurland S, Zhan M, Bradham DD, Roghmann MC: **Comparison of mortality risk associated with bacteremia due to methicillin-resistant and methicillin sensitive *Staphylococcus Aureus*.** *Infect Control Hosp Epidemiol* 2007, **28**:273-279.
- Cosgrove SE, Sakoulas G, Perencevich EN, Schwaber MJ, Karchmer AW, Carmeli Y: **Comparison of mortality associated with methicillin-resistant and methicillin susceptible *Staphylococcus aureus* bacteremia: a meta-analysis.** *Clin Infect Dis* 2003, **36**:53-59.
- Community-Associated Methicillin Resistant *Staphylococcus aureus* (CA-MRSA).** [[http://www.cdc.gov/ncidod/dhqp/ar\\_mr\\_sa\\_ca.html](http://www.cdc.gov/ncidod/dhqp/ar_mr_sa_ca.html)]
- Naimi TS, LeDell KH, Como-Sabetti K, Borchardt SM, Boxrud DJ, Etienne J, Johnson SK, Vandenesch F, Fridkin S, O'Boyle C, Danila RN, Lynfield R: **Comparison of community- and health care-associated methicillin-resistant *Staphylococcus aureus* infection.** *JAMA* 2003, **290**:2976-2984.
- Campbell KM, Vaughn AF, Russell KL, Smith B, Jimenez DL, Barrozo CP, Minarcik JR, Crum NF, Ryan MA: **Risk factors for community-associated methicillin-resistant *Staphylococcus aureus* infections in an outbreak of disease among military trainees in San Diego, California, in 2002.** *J Clin Microbiol* 2004, **42**:4050-4053.
- Udo EE, Pearman JW, Grubb WB: **Genetic Analysis of community isolates of methicillin-resistant *Staphylococcus aureus* in Western Australia.** *J Hosp Infect* 1993, **25**:97-108.
- Centers for Disease Control and Prevention: **Four pediatric deaths from community-acquired methicillin-resistant *Staphylococcus aureus* - Minnesota and North Dakota.** *JAMA* 1999, **282**:1123-1125.
- Fridkin SK, Hageman JC, Morrison M, Sanza LT, Como-Sabetti K, Jernigan JA, Harriman K, Harrison LH, Lynfield R, Farley MM: **Methicillin-resistant *Staphylococcus aureus* in three communities.** *N Engl J Med* 2005, **352**:1436-1444.
- King MD, Humphrey BJ, Wang YF, Kourbatova EV, Ray SM, Blumberg HM: **Emergence of community-acquired methicillin-resistant. *Staphylococcus aureus* USA 300 clone as the predominant cause of skin and soft tissue infections.** *Ann Intern Med* 2006, **144**:309-317.
- Francis JS, Doherty MC, Lopatin U, Johnston CP, Sinha G, Ross T, Cai M, Hansel NN, Perl T, Ticehurst JR, Carroll K, Thomas DL, Nuermberger E, Bartlett JG: **Severe community-onset pneumonia in healthy adults caused by methicillin-resistant *Staphylococcus aureus* carrying the Pantone Valentine leukocidin genes.** *Clin Infect Dis* 2005, **40**:100-107.
- Miller LG, Perdreau-Remington F, Rieg G, Mehdi S, Perloth J, Bayer AS, Tang AW, Phung TO, Spellberg B: **Necrotizing fasciitis caused by community-associated methicillin-resistant *Staphylococcus aureus* in Los Angeles.** *N Engl J Med* 2005, **352**:1445-1453.
- Boucher HW, Corey GR: **Epidemiology of Methicillin-Resistant *Staphylococcus aureus*.** *Clin Infect Dis* 2008, **46**:S344-9.
- Gregg CR, Rogers TE, Munford RS: **Xanthogranulomatous Pyelonephritis.** *Curr Clin Top Infect Dis* 1999, **19**:287-304.
- Povýsil C, Koniková L: **Experimental Xanthogranulomatous Pyelonephritis.** *Invest Urol* 1972, **9**:313-318.
- Treadwell TL, Craven DE, Delfin H, Stilmant MM, McCabe WR: **Xanthogranulomatous Pyelonephritis Caused by Methicillin-Resistant *Staphylococcus aureus*.** *Am J Med* 1984, **76**:533-537.
- Moran GJ, Krishnadasan A, Gorwitz RJ, Fosheim GE, McDougal LK, Carey RB, Talan DA: **Methicillin-resistant *S. aureus* infections among patients in the emergency department.** *N Engl J Med* 2006, **355**:666-674.
- Abreu DA, Osorio F, Guido LG, Carvalhal GF, Mouro L: **Retroperitoneal Infections by Community Acquired Methicillin Resistant *Staphylococcus Aureus*.** *J Urol* 2008, **179**:172-176.
- Zorzos I, Moutzouris V, Korakianitis G, Katsou G: **Analysis of 39 Cases of Xanthogranulomatous Pyelonephritis with Emphasis on CT Findings.** *Scand J Urol Nephrol* 2003, **37**:342-347.
- Goyal R, Mandhani A, Dubey D, Srivastava A, Kumar A: **Is laparoscopic nephrectomy the preferred approach in xanthogranulomatous pyelonephritis?** *Urology* 2006, **68**:952-955.