

Case report

Fetal nuchal cystic hygroma associated with aortic coarctation and trisomy 21: a case report

Sohei Kitazawa*, Kiyoshi Mori, Takeshi Kondo and Riko Kitazawa

Address: Division of Pathology (Diagnostic Molecular Pathology Unit), Kobe University Graduate School of Medicine, 7-5-1 Kusunoki-cho, Chuo-ku, Kobe 650-0017, Japan

Email: SK* - kitazawa@med.kobe-u.ac.jp; KM - kiyoshim@med.kobe-u.ac.jp; TK - kondo@med.kobe-u.ac.jp; RK - riko@med.kobe-u.ac.jp

* Corresponding author

Received: 15 June 2009 Accepted: 18 July 2009 Published: 4 August 2009

Cases Journal 2009, **2**:8280 doi: 10.4076/1757-1626-2-8280

This article is available from: <http://casesjournal.com/casesjournal/article/view/8280>

© 2009 Kitazawa et al.; licensee Cases Network Ltd.

This is an Open Access article distributed under the terms of the Creative Commons Attribution License (<http://creativecommons.org/licenses/by/3.0>), which permits unrestricted use, distribution, and reproduction in any medium, provided the original work is properly cited.

Abstract

We report a case of fetal nuchal cystic hygroma associated with aortic coarctation and trisomy 21. A stillborn baby, delivered at 15 weeks and 5 days of gestation, had a huge nuchal cystic hygroma. Autopsy revealed aortic coarctation of the periductal type with patent ductus arteriosus, endocardial cushion defect and left ventricular hypoplasia. Trisomy 21 was evident by karyotyping. Macroscopically, while an apparent association of nuchal cystic hygroma and aortic coarctation resembled Turner syndrome, histopathological findings were those typically seen in trisomy 21: numerous dilated lymphatics in the subcutaneous tissue with severe mesenchymal edema, and an enlarged jugular lymphatic sac.

Introduction

Various lymphatic abnormalities cause jugular lymphatic distension resulting in nuchal edema and cystic hygroma [1,2]. Increased nuchal translucency by ultrasound examination directly reflects the presence of nuchal edema and cystic hygroma, and is regarded as a marker for aneuploidy such as Turner syndrome or trisomy of various chromosomes [3,4]. Here, the rare occurrence of a huge congenital fetal nuchal hygroma associated with complex cardiac anomalies including aortic coarctation in a trisomy 21 case is described.

Case presentation

A stillborn Japanese baby, delivered at 15 weeks and 5 days of gestation, weighed 145 g and measured 16.6 cm

long. At autopsy, no apparent malformation was noted except for a huge nuchal cystic mass measuring 20 × 15 mm, (Figure 1A, arrows) from the external aspect. Histopathological examination of the nuchal mass revealed numerous dilated lymphatics with proliferation of spindle-shaped mesenchymal cells and edema in the subcutaneous area (Figure 1B, HE, ×200). The heart, weighing 1.5 g, showed coarctation of the aortic arch (Figure 2A, asterisks) with prominent patent ductus arteriosus (Figure 2A and 2B, arrows). Endocardial cushion defect and slight left ventricular hypoplasia were also noted. Karyotypic analysis of the fetal blood showed trisomy of chromosome 21 (data not shown), and a definitive diagnosis of nuchal cystic hygroma associated with trisomy 21 and aortic coarctation was made.

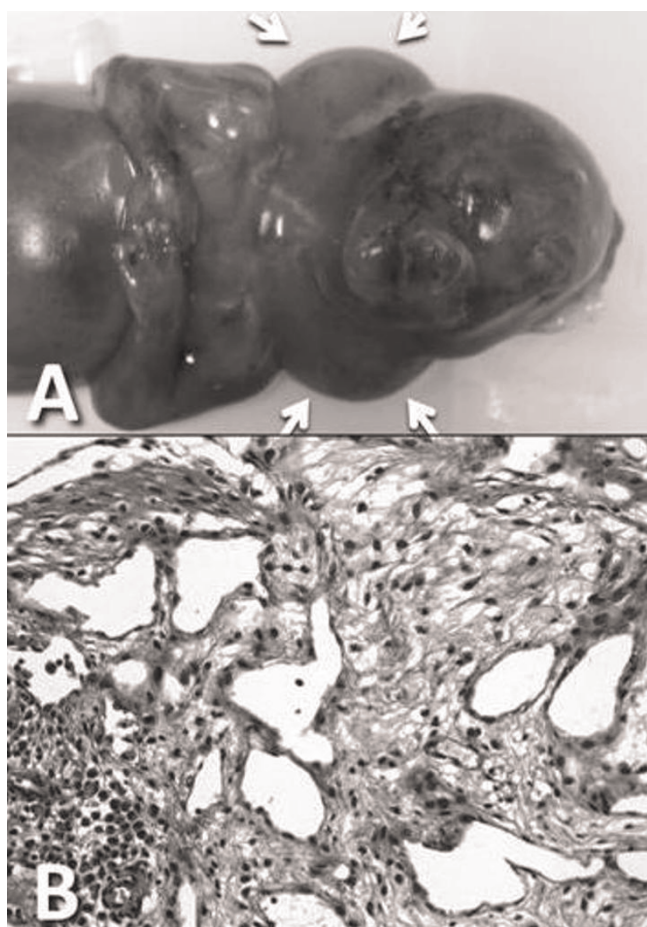


Figure 1. Macroscopic and microscopic findings of the cystic hygroma. **(A)** a huge nuchal cystic mass measuring 20×15 mm is observed around the neck (arrows). Externally, no other apparent malformations are noted. **(B)** Histopathological examination revealed numerous dilated lymphatics with proliferation of spindle-shaped mesenchymal cells and edema in the subcutaneous area (HE, $\times 200$).

Discussion

Nuchal edema or cystic hygroma observed as increased nuchal translucency by ultrasound examination is regarded as a marker for aneuploidy. Since nuchal cystic hygroma is frequently associated with Turner syndrome with aortic coarctation, nuchal translucency is used as a marker for the antenatal diagnosis of aortic coarctation also [5]. Indeed, studies by Ph Descamps et al. have shown that Turner syndrome (45X) and Down's syndrome (trisomy 21) comprise nearly half the cases of nuchal cystic hygroma [3]. The mechanism whereby each chromosomal abnormality develops nuchal edema or cystic hygroma is thought to be different, however [6]. Histopathologically, cases with Down's syndrome are also different from those with Turner syndrome in that the

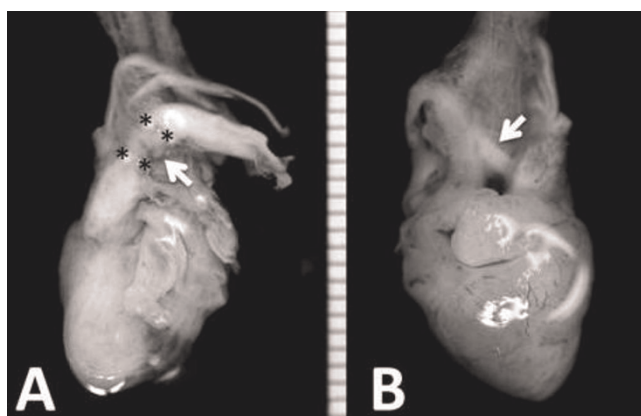


Figure 2. The heart, from anterior **(A)** and posterior **(B)** views. The heart weighed 1.5 g and showed coarctation of the aortic arch **(A, asterisks)** with prominent patent ductus arteriosus **(A and B, arrows)**.

former have an enlarged jugular lymphatic sac with numerous dilated lymphatics in the subcutaneous tissue with severe mesenchymal edema [6]. In our present case, while an apparent association of nuchal cystic hygroma and aortic coarctation suggested the presence of Turner syndrome, histopathological findings were those typically seen in trisomy 21.

Consent

Written informed consent was obtained from the baby's family for the publication of this case report with accompanying images. A copy of the written consent is available for viewing by the Editor-in-Chief of the journal.

Competing interests

The authors declare that they have no competing interests.

Authors' contributions

All authors analyzed and interpreted the patient data regarding the hematological disease and the autopsy. SK and KM conducted the histological examinations, and SK was the major contributor in writing the manuscript. All authors read and approved the final manuscript.

References

1. Azar GB, Snijders RJ, Gosden C, Nicolaides KH: **Fetal nuchal cystic hygromata: associated malformations and chromosomal defects.** *Fetal Diagn Ther* 1991, **6**:46-57.
2. Beke A, Joó JG, Csaba A, Lázár L, Bán Z, Papp C, Tóth-Pál E, Papp Z: **Incidence of Chromosomal Abnormalities in the Presence of Fetal Subcutaneous Oedema, Such as Nuchal Oedema, Cystic Hygroma and Non-Immune Hydrops.** *Fetal Diagn Ther* 2009, **25**:83-92.
3. Descamps P, Jourdain O, Paillet C, Toutain A, Guichet A, Pourcelot D, Gold F, Castiel M, Body G: **Etiology, prognosis and management of nuchal cystic hygroma: 25 new cases and literature review.** *Eur J Obstet Gynecol Reprod Biol* 1997, **71**:3-10.

4. Yoshida S, Miura K, Yamasaki K, Miura S, Shimada T, Tanigawa T, Yoshida A, Nakayama D, Masuzaki H: **Does increased nuchal translucency indicate a fetal abnormality? A retrospective study to clarify the clinical significance of nuchal translucency in Japan.** *J Hum Genet* 2008, **53**:688-693.
5. Moselhi M, Thilaganathan B: **Nuchal translucency: a marker for the antenatal diagnosis of aortic coarctation.** *Br J Obstet Gynaecol* 1996, **103**:1044-1045.
6. Bekker MN, van den Akker NM, de Mooij YM, Bartelings MM, van Vugt JM, Gittenberger-de Groot AC: **Jugular lymphatic maldevelopment in Turner syndrome and trisomy 21: different anomalies leading to nuchal edema.** *Reprod Sci* 2008, **15**:295-304.

Do you have a case to share?

Submit your case report today

- Rapid peer review
- Fast publication
- PubMed indexing
- Inclusion in Cases Database

Any patient, any case, can teach us something



**CASES
NETWORK**

www.casesnetwork.com