

## Case Report

## Open Access

# Nocardia – Opportunistic chest infection in elderly: A case report

Kaushik Sanyal\* and Kanagasabesan Sabanathan

Address: Department of Medicine, Norfolk and Norwich University Hospital, Norwich, UK

Email: Kaushik Sanyal\* - ksanyal01@doctors.org.uk; Kanagasabesan Sabanathan - kamax.sabanathan@nnuh.nhs.uk

\* Corresponding author

Published: 21 August 2008

Received: 8 August 2008

Cases Journal 2008, 1:122 doi:10.1186/1757-1626-1-122

Accepted: 21 August 2008

This article is available from: <http://www.casesjournal.com/content/1/1/122>

© 2008 Sanyal and Sabanathan; licensee BioMed Central Ltd.

This is an Open Access article distributed under the terms of the Creative Commons Attribution License (<http://creativecommons.org/licenses/by/2.0>), which permits unrestricted use, distribution, and reproduction in any medium, provided the original work is properly cited.

### Abstract

In this rare case a non-immunocompromised patient with old Tuberculosis on low dose of steroids presents with opportunistic infection of a weakly aerobic gram positive acid fast, filamentous bacteria called Nocardia.

An 80 year old non-smoking white female presented with cough, shortness of breath and purulent sputum.

Initial antibiotics given were not helpful. Later microbial diagnosis was Nocardia in sputum sample which was uncommon in a non-immunocompromised. She responded to co-trimoxazole therapy.

### Background

Nocardia organism is filamentous gram positive rods. They are aerobic. Human pathogens infect by inhalation of airborne bacilli or the traumatic inoculation of organism into skin. Overall 80% present as invasive pulmonary infection, disseminated disease abscess; 20% present as cellulitis. Debilitated patients have a 45% mortality rate even with appropriate therapy.

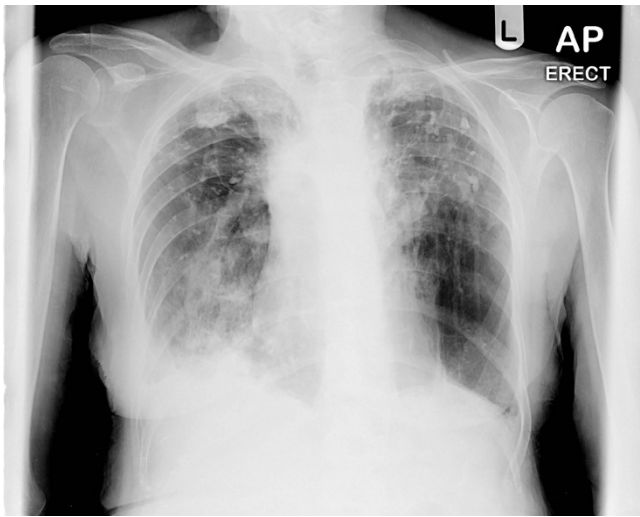
### Case presentation

An 80 year old non-smoker white female was admitted with shortness of breath and cough with purulent sputum. Relevant past history of polymyalgia rheumatica, for which she was on regular low dose steroids. She also informed past history of Tuberculosis (in 1951) treated in sanatorium. She was hypoxic with oxygen saturation 79.9% on air. Her inflammatory markers were high. Chest X-ray [Fig 1] and Computed tomographic scan [Fig 2] revealed old calcification of right apical lobe and consolidation and bronchiectatic changes of right lower lobe. She was treated with bronchodilators and antibiotics. She was still hypoxic with high inflammatory markers. The micro-

bial diagnosis was established after isolating Nocardia in sputum sample. Subsequently she was subsequently treated with trimethoprim and sulphamethoxazole for 6 months and offered further follow-up. Further follow-up clinic we found out that she responded to the treatment.

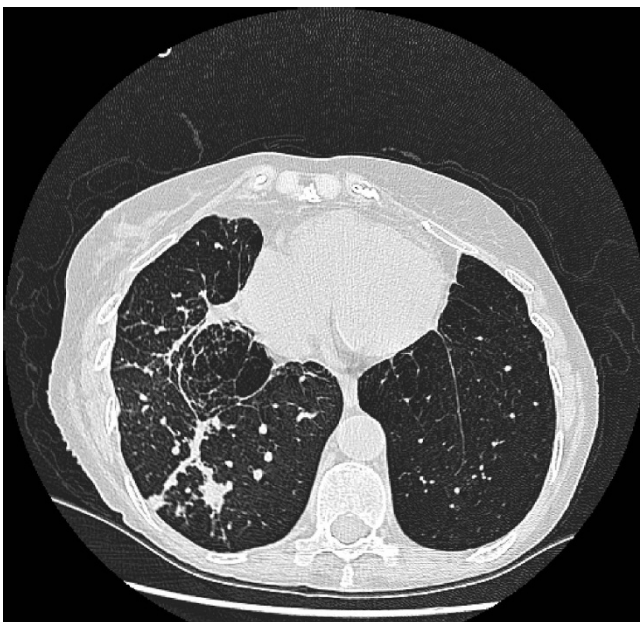### Discussion

In this report, we present a rare case of a non-immunocompromised patient with old Tuberculosis but she has been on low dose of steroids. Nocardia is a weakly aerobic gram positive acid fast, filamentous bacteria. They are an important opportunistic infection in elderly and immunocompromised affecting lung, brain and skin. Nocardiosis is sporadic and have higher incidence in the immunocompromised population. There is no age, race predilection [1]. Pre-existing lung condition, in this of case of tuberculosis increase the risk of contracting the infection. Bronchiectasis is an important risk factor of Nocardia colonisation. The presentations are cough, fever and difficulties in breathing. The spread is sporadic, and are usually found in dust and soil. The use of Ziehl Neelson technique with a weaker acid concentration can result



**Figure 1**  
Chest X-ray showing consolidation and bronchiectatic changes.

in identification of a variety of acid fast organisms [2]. Generalised infection involves cutaneous joint and pulmonary cause. Further dissemination involves acute and chronic symptoms. There are no person to person transmission. Core diagnostic test include sputum culture and bronchoscopy.



**Figure 2**  
CT scan showing bronchiectatic cavity of old tuberculosis which grew *Nocardia*.

Standard therapy is trimethoprim-sulphamethoxazole for 6 months to 1 year. Refractory case needs imipenem and amikacin. *Nocardia* should be suspected in immunosuppressed patients.

### Conclusion

Pulmonary bronchiectasis is difficult to diagnose, which delays its diagnosis and a high level of suspicion is required in patients with underlying chronic condition or chronic steroid use [3]. *Nocardia* when involves the central nervous system leads to a poor prognosis, implies an early diagnosis and prompt treatment. Death occurs from sepsis, overwhelming pneumonia or brain abscess. Mortality is increased in disseminated disease involving 2 or more organs [4]. Mortality is more in patients on corticosteroids or chemotherapy. *Nocardiosis* should be an important differential of any chronic pneumonia not responding to the antibiotic treatment.

### Competing interests

The authors declare that they have no competing interests.

### Authors' contributions

KS carried out literature search. KS participated in the sequence alignment and draft of manuscript. All authors read and approved the final manuscript

### Acknowledgements

Written consent has been obtained from the patient for submission of this manuscript and figures for publication. Funding was neither sought nor obtained.

### References

1. Bocchino M, Paglia MG, Marruchella A, Contini S, Festa A, Saltini C: **Molecular Diagnosis of Fatal *Nocardia farcinica* Pneumonia in an HIV-Negative Patient.** *Respiration* 2008, **75(4)**:461-5. 2006 Jun 30;
2. Olson ES, Simpson AJ, Norten AJ, Das SS: **Not everything acid fast Is *Mycobacterium Tuberculosis*.** *J Clin Pathol* 1998, **51(7)**:535-6.
3. Menéndez R, Cordero PJ, Santos M, Gobernado M, Marco V: **Pulmonary Infection with *Nocardia* species: a report of 10 cases and review.** *The European respiratory journal* 1997, **10(7)**:1542-6. 28.
4. Martínez-Albaladejo M, González-Pina B, Alguacil-García G, de Pacomoya M: **[Pulmonary *Nocardiosis* in non-immunocompromised patient].** *An Med Interna* 1995, **12(8)**:413-4.

Publish with **BioMed Central** and every scientist can read your work free of charge

"BioMed Central will be the most significant development for disseminating the results of biomedical research in our lifetime."

Sir Paul Nurse, Cancer Research UK

Your research papers will be:

- available free of charge to the entire biomedical community
- peer reviewed and published immediately upon acceptance
- cited in PubMed and archived on PubMed Central
- yours — you keep the copyright

Submit your manuscript here:  
[http://www.biomedcentral.com/info/publishing\\_adv.asp](http://www.biomedcentral.com/info/publishing_adv.asp)

