

Case Report

Open Access

## Doxycycline-induced ulceration mimicking esophageal cancer

Veysel Tahan\*<sup>1</sup>, Hakan Sayrak<sup>2</sup>, Nevzat Bayar<sup>3</sup>, Burak Erer<sup>4</sup>, Gulgun Tahan<sup>5</sup> and Faysal Dane<sup>6</sup>

Address: <sup>1</sup>Department of Gastroenterology, Pasabahce State Hospital, Istanbul, Turkey, <sup>2</sup>Department of Pathology, Pasabahce State Hospital, Istanbul, Turkey, <sup>3</sup>Department of Internal Medicine, Pasabahce State Hospital, Istanbul, Turkey, <sup>4</sup>Department of Internal Medicine Umraniye State Hospital, Istanbul, Turkey, <sup>5</sup>Surgery Unit, Institute of Gastroenterology, Marmara University, Istanbul, Turkey and <sup>6</sup>Department of Oncology, Marmara University School of Medicine, Istanbul, Turkey

Email: Veysel Tahan\* - veytahan@yahoo.com; Hakan Sayrak - hakan@sayrak.com; Nevzat Bayar - nevzatbayar@yahoo.com; Burak Erer - burakerer@yahoo.com; Gulgun Tahan - gulgunsahintahan@yahoo.com; Faysal Dane - faysaldane2001@yahoo.com

\* Corresponding author

Published: 8 September 2008

Received: 19 July 2008

Cases Journal 2008, 1:144 doi:10.1186/1757-1626-1-144

Accepted: 8 September 2008

This article is available from: <http://www.casesjournal.com/content/1/1/144>

© 2008 Tahan et al; licensee BioMed Central Ltd.

This is an Open Access article distributed under the terms of the Creative Commons Attribution License (<http://creativecommons.org/licenses/by/2.0>), which permits unrestricted use, distribution, and reproduction in any medium, provided the original work is properly cited.

### Abstract

**Introduction:** Doxycycline-induced esophageal ulcer patients are mostly young persons with no history of esophageal dysfunction. Heartburn, midsternal pain and dysphagia are the most common symptoms. It has generally a benign course. The present case is the first report of doxycycline-induced extensive ulcerations, mimicking esophageal cancer in two esophageal segments alongside, in the literature.

**Case presentation:** This report describes a 16-year-old Caucasian girl who, while taking doxycycline capsules 100 mg twice a day for acne vulgaris for 3 months, developed these symptoms. An upper endoscopy revealed multiple circumferential deep ulcerations surrounding fragile, irregular, hyperemic and hypertrophic mucosa at the level of the mid-esophagus and concomitantly in the lower esophageal sphincter. The lesions were biopsied to exclude esophageal carcinoma because of the suspicious appearance in the endoscopic examination. The histopathological examination, haematoxylin and eosin stained sections showed ulceration with a mixed inflammatory infiltrate. Doxycycline was discontinued and she was given sucralfate 1 g qid and omeprazole 20 mg bid orally. All symptoms of the patient were resolved on the third day of the treatment. After 4 weeks of the therapy, an upper endoscopic control examination demonstrated normal findings.

**Conclusion:** The present case has been an uncommon presentation of doxycycline-induced extensive ulcerations, mimicking esophageal cancer in two esophageal segments, concomitantly. Even the lesions were biopsied to exclude esophageal carcinoma. A modification on the behavior of taking drugs can prevent these unpleasant complications.

### Introduction

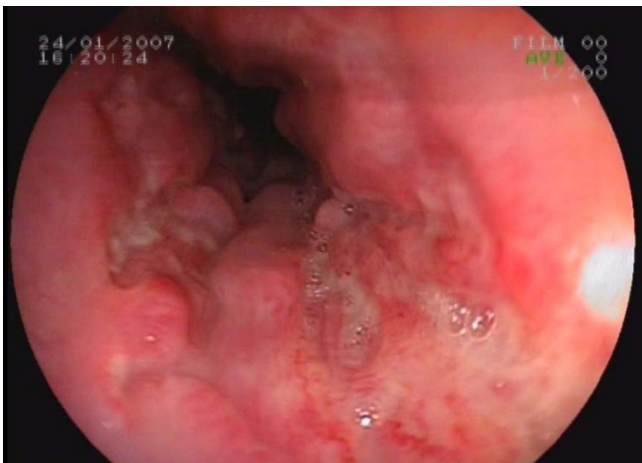
Doxycycline-induced esophageal lesions had been examined mostly as mild esophagitis and sometimes as ulceration with a generally benign course. Common reason of

this complication has been taking medications just before bedtime, and with a small amount of water [1,2]. In general the certain drugs tend to cause the damage in a singular segment, as doxycycline in mid-esophageal segment

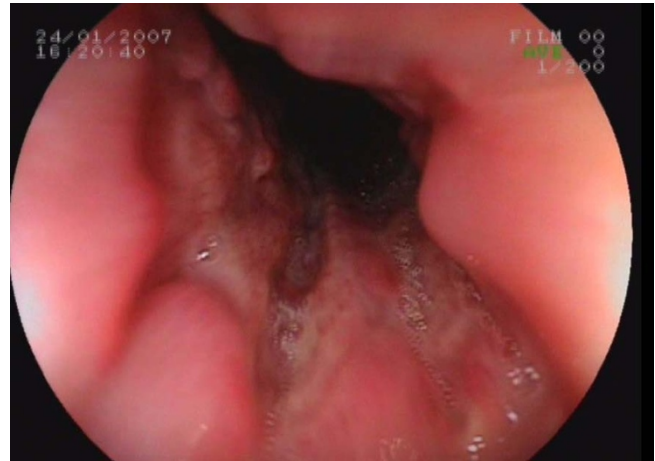[3]. Here we present a severe, unusual endoscopic appearance of a case of doxycycline-induced esophageal ulcers and tissue fragility mimicking esophageal cancer in the lower and mid-esophageal segments, simultaneously.

### Case report

A 16-year-old Caucasian girl was admitted to our outpatient clinic with complains of heartburn, midsternal pain and dysphagia for 4 weeks. She had no fever, cough or any additional complain. Her cardiac and chest auscultation and throat examination were normal. Her whole blood count and erythrocyte sedimentation rate were also normal. Her electrocardiography and chest x-ray revealed no pathological findings. An upper endoscopy revealed multiple circumferential deep ulcerations surrounding fragile, irregular, hyperemic and hypertrophic mucosa at the level of the mid-esophagus (Figure 1) and lower esophageal sphincter (Figure 2). Because of the suspicious endoscopic appearance, the lesions were biopsied to exclude esophageal carcinoma. In her detailed history, she was taking doxycycline capsules 100 mg twice a day for acne vulgaris for 3 months. She was swallowing only the capsule in the recumbent position at midnight. In the histopathological examination, haematoxylin and eosin stained sections showed ulceration with a mixed inflammatory infiltrate (Figure 3). Doxycycline was discontinued and she was given sucralfate 1 g qid and omeprazole 20 mg bid orally to control of gastric acid reflux until her symptoms resolve. All symptoms of the patient were dramatically resolved on the third day of the treatment. A control endoscopy demonstrated normal findings, after 4 weeks of the therapy.



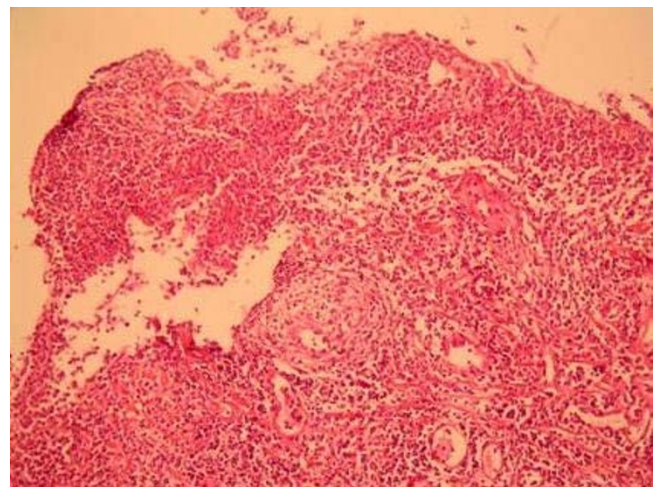
**Figure 1**  
**Endoscopic appearance of the ulcers mimicking cancer at the level of the mid-esophagus.** An upper endoscopic examination revealed multiple circumferential deep ulcerations surrounding fragile, irregular, hyperemic and hypertrophic mucosa at the level of the mid-esophagus.



**Figure 2**  
**Endoscopic appearance of the ulcers mimicking cancer in the lower esophageal sphincter.** Same endoscopic findings of the mid-esophagus were observed in the lower esophageal sphincter.

### Discussion

Drug-induced ulcer is thought not to be so common; however it is not an unusual clinical condition especially in patients taking certain drugs. Doxycycline-induced esophageal ulcer patients are mostly young persons with no history of esophageal dysfunction. The main reason for an increased transit time is to take the medication with a small amount of water immediately before sleeping, as the present case did [1,2]. Drug-induced esophagitis is more frequent with capsule than with tablet, because of its easier adhesion to the esophageal surface [4]. As an acidic



**Figure 3**  
**Histopathological section of the ulcer tissue.** Histopathological section of the ulcer tissue showed ulceration with a mixed inflammatory infiltrate (HE,  $\times 100$ ).

drug, doxycycline accumulation in the epithelial cells can also cause a focal contact esophagitis. With its subsequent local cytochemical effects, doxycycline can cause ulceration and friability of the adjacent esophageal mucosa. In addition, doxycycline can also inhibit protein synthesis functions in the esophagus [5,6].

Nevertheless history and upper endoscopy can confirm the diagnosis in almost all cases. In suspected conditions, exclusion of esophageal carcinoma by histology can be necessary [2], as it was the case in our patient.

Gencosmanoglu et al. revealed that tetracycline tends to cause distal esophagitis and doxycycline is more frequently associated with mid-esophageal ulceration [3]. However, in the present case, we identified doxycycline-induced ulcers in both distal and mid-esophageal localizations. Drug-induced esophagitis should be suspected in all patients presenting with chest pain and dysphagia and is a preventable cause of morbidity that consists of giving simple advice of how and when to take medication. The prevention could be achieved by swallowing the drug with at least 100 ml of water after swallowing the medication and remaining in the upright position thereafter.

In conclusion, the present case has been an uncommon presentation of doxycycline-induced extensive ulcerations, mimicking esophageal cancer in two esophageal segments. A modification on the behavior of taking drugs can prevent these unpleasant complications.

### Competing interests

The authors declare that they have no competing interests.

### Authors' contributions

VT performed endoscopic examination, took pictures and biopsies from the lesions. HS performed histopathologic examinations of the biopsies and took pictures of the tissues. NB interned the patient in the Internal Medicine Clinic and performed biochemical and hematological studies. BE: followed up the patient and a contributor in writing the manuscript. GT performed the control endoscopy after the therapy and was a major contributor in writing the manuscript. FD interpreted the patient data regarding the oncological disease. All authors read and approved the final manuscript.

### Consent section

Written informed consent was obtained from the patient for publication of this case report and accompanying images. A copy of the written consent is available for review by the Editor-in-Chief of this journal.

### Acknowledgements

The authors would like to thank Dr. Mithat Yardým, Head of Pasabahce State Hospital, for his support for materials essential for the study.

### References

1. Isler M: **Doxycycline-induced esophageal ulceration.** *Mil Med* 2001, **166**:203-222.
2. Kadayifci A, Gulsen MT, Koruk M, Savas MC: **Doxycycline-induced pill esophagitis.** *Dis Esophagus* 2004, **17**:168-71.
3. Gencosmanoglu R, Kurtkaya-Yapicier O, Tiftikci A, Avsar E, Tozun N, Oran ES: **Mid-esophageal ulceration and candidiasis-associated distal esophagitis as two distinct clinical patterns of tetracycline or doxycycline-induced esophageal injury.** *J Clin Gastroenterol* 2004, **38**:484-9.
4. Champel V, Jonville-Bera AP, Bera F, Autret E: **Esophageal involvement after tetracycline ingestion.** *Therapie* 1997, **52**:587-9.
5. Kikendall JW, Friedman AC, Oyewole MA, Fleischer D, Johnson LF: **Pill-induced esophageal injury. Case reports and review of the medical literature.** *Dig Dis Sci* 1983, **28**:174-82.
6. Biller JA, Flores A, Buie T, Mazor S, Katz AJ: **Tetracycline-induced esophagitis in adolescent patients.** *J Pediatr* 1992, **120**:144-5.

Publish with **BioMed Central** and every scientist can read your work free of charge

"BioMed Central will be the most significant development for disseminating the results of biomedical research in our lifetime."

Sir Paul Nurse, Cancer Research UK

Your research papers will be:

- available free of charge to the entire biomedical community
- peer reviewed and published immediately upon acceptance
- cited in PubMed and archived on PubMed Central
- yours — you keep the copyright

Submit your manuscript here:  
[http://www.biomedcentral.com/info/publishing\\_adv.asp](http://www.biomedcentral.com/info/publishing_adv.asp)

