



Case report

An unusual groin mass. Seminal vesicle abscess: a case report

Sunita Saha^{1*}, Georgina Wright¹, Tan Arulampalam² and John Corr³

Address: ¹Department of General Surgery, ²Department Laparoscopic and General Surgery and ³Department of Urology, Colchester General Hospital, Turner Road, Colchester, Essex, CO4 5JU, UK

Email: SS* - sahasunita@hotmail.com; GW - georginawright@doctors.net; TA - tanarulampalam@essexrivers.nhs.uk; JC - johncorr@essexrivers.nhs.uk

* Corresponding author

Published: 14 May 2009

Received: 8 November 2008

Cases Journal 2009, 2:6531 doi: 10.1186/1757-1626-2-6531

Accepted: 13 February 2009

This article is available from: <http://casesjournal.com/casesjournal/article/view/6531>

© 2009 Saha et al; licensee Cases Network Ltd.

This is an Open Access article distributed under the terms of the Creative Commons Attribution License (<http://creativecommons.org/licenses/by/3.0>), which permits unrestricted use, distribution, and reproduction in any medium, provided the original work is properly cited.

Abstract

The rare pathology of seminal vesicle abscess is usually diagnosed with computerised tomography scan and confirmed with transrectal ultrasound. We report a recently encountered case where diagnosis proved difficult owing to the non-specific clinical presentation.

Introduction

Seminal vesicle abscess is a rarely encountered pathology with only 28 reported cases in the English literature. Commonly reported presenting complaints include; fever, dysuria and other urogenital symptoms. Here we present a case of seminal vesicle abscess that we believe to be the first reported case presenting with a tender lump in the groin. We describe the diagnostic challenge of this unknown presentation and its subsequent management.

Case presentation

We report a case of a 49 year old childless Caucasian male who presented with a one week history of a gradually enlarging, exquisitely tender groin mass. The patient denied systemic, bowel or genitourinary symptoms except on deeper questioning when a two week history of darkened urine was described. Past medical history included bilateral groin hernia repair as a child and an incision and drainage of perianal abscess one year before.

Clinical examination revealed a tender mass in the left groin extending into the left scrotum where a large cystic swelling was identified. A non-tender right testicle was palpated. The remainder of clinical examination including rectal examination was unremarkable.

Haematological indices demonstrated a mild neutrophilia and abnormal liver function tests. In view of these findings, a groin exploration was performed demonstrating a thick walled sac adherent to the vas and vessels. Surprisingly when incised, this drained >100ml of frank pus into which a corrugated drain was inserted. The pus later cultured coliform bacteria.

Computerised tomography of the abdomen and pelvis revealed a thick-wall collection between the urinary bladder and rectosigmoid colon. In order to further delineate the extent of disease magnetic resonance imaging (Figure 1) was performed. This demonstrated a collection draining along the spermatic cord pointing to the left inguinal region.

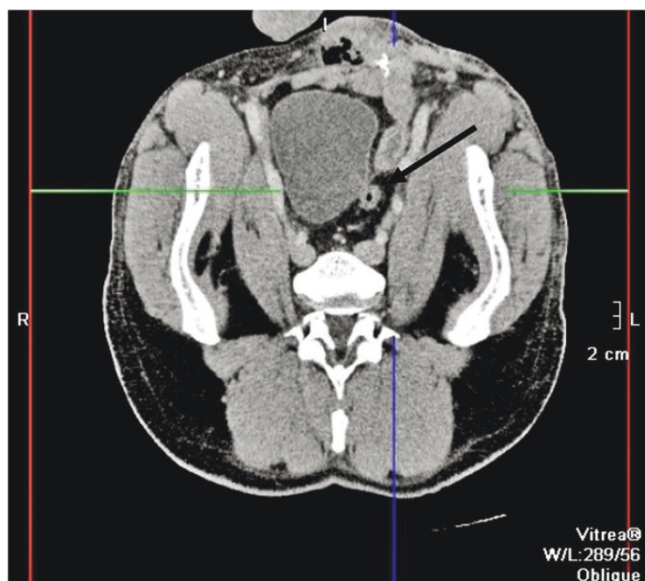


Figure 1. Transverse section magnetic resonance image demonstrating seminal vesicle abscess (arrowed).

In view of the likely urological source, a cystoscopy, rigid sigmoidoscopy to 15cm and laparoscopic drainage of the abscess were performed. Laparoscopic findings suggested the source to be the seminal vesicle; this was later confirmed by histological analysis.

A follow-up scan performed eleven days later confirmed successful drainage. Although there were no local complications, unfortunately the patient presented one month later with a pulmonary embolus and however made a good recovery.

Discussion

Raijfer et al [1] first reported a case of seminal vesicle abscess in 1978 who presented with the classical features of fever and prostatic mass. Seminal vesicle abscesses are a rare entity with only a further 27 cases reported in the English literature [2–4]. A review by Pandey et al documented the clinical presentations of reported cases with 74% presenting with fever, 58% with dysuria and 32% with a tender prostate or ongoing epididymo-orchitis. The case described above exhibited none of the principal features described in this article [2]. A number of differential diagnoses exist for a tender groin mass including a groin abscess however to the authors knowledge this is the first documented case of the source being a seminal vesicle. Ryan and Harte [5] report a similar case of suppurative prostatitis presenting as an inguinal mass with no involvement of the seminal vesicle.

Although the exact aetiology of seminal vesicle abscess is unclear, reported predisposing factors include urinary tract infection, diabetes, indwelling catheters, urological instrumentation/surgery, intraabdominal carcinomatosis and anatomical abnormalities [6–8]. Following eventual diagnosis, retrospective review of imaging suggested that the causative factor in this case was likely to have been a congenital anatomical anomaly of the ejaculatory duct. This presumption is supported by the fact that patient was subfertile.

In previous documented cases the most common causative organism is *Escherichia coli*. In fact, a study by Saglam et al. cultured *Escherichia coli* from the urine and abscess in 100% of cases [3]. This correlates with our findings.

Computerised tomography is the most frequently described diagnostic tool, although the most recent literature advocates the use of transrectal ultrasound [3]. The unusual nature of presentation in this case resulted in a delayed diagnosis which was made at the time of surgical exploration. Current recognised treatment modalities are; needle drainage via a transrectal or transperineal approach [6]. Laparoscopic drainage although not the recommended treatment, it proved to be effective in this instance.

Tender groin lumps are common in general surgical practice. We describe the first case of a seminal vesicle abscess being the underlying pathology.

Consent

Written informed consent was obtained from the patient for publication of this case report and accompanying images. A copy of the written consent is available for review.

Competing interests

The authors declare they have no competing interests.

Authors' contributions

SS and GW contributed to conception and drafting of the manuscript, TA and JC contributed to revision and final approval of manuscript.

References

1. Raijfer J, Egglestone JC, Sanders RC, Walsh PC: **Fever and prostatic mass in a young man.** *J Urol.* 1978, **119**:555-558.
2. Pandey P, Peters J, Shingleton W: **Seminal vesicle abscess: A case report and review of the literature.** *Scand J Urol Nephrol.* 1995, **29**:521-524.
3. Saglam M, Ugurel S, Kilciler M, Tasar M, Somuncu I, Ücoz T: **Transrectal ultrasound-guided transperineal and transrectal management of seminal vesicle abscesses.** *Eur J Radiol.* 2004, **52**:329-334.
4. Dewani CP, Dewani N, Bhatia D: **Case report: tubercular cold abscess of seminal vesicle: minimally invasive endoscopic management.** *J Endourol.* Jun 2006, **20**(6):436-442.

5. Ryan SP, Harte PJ: **Suppurative inflammation of vas deferens: an unusual groin mass.** *Urology.* Mar 1988, **31**(3):245-246.
6. Fox C, Vaccaro J, Kiesling V, Belville W: **Seminal vesicle abscess: The use of computerized coaxial tomography for diagnosis and therapy.** *J Urol.* 1998, **139**:384-385.
7. Zagoria R, Papanicolaou N, Pfister R, Stafford S, Young H: **Seminal vesicle abscess after vasectomy: Evaluation by transrectal sonography and CT.** *Am J. Roent.* 1987, **149**:137-138.
8. Gulankiar A, Clark J, Feliz T: **Prostatic abscess: an unusual presentation of metastatic prostate cancer.** *Br J Urol.* 1998, **82**:309-310.

Do you have a case to share?

Submit your case report today

- Rapid peer review
- Fast publication
- PubMed indexing
- Inclusion in Cases Database

Any patient, any case, can teach us something



**CASES
NETWORK**

www.casesnetwork.com