



Case report

Colonoscopy assisted laparoscopic sigmoidectomy: a case report

Satoru Takayama* and Hiromitsu Takeyama

Address: Department of Gastroenterological Surgery, Nagoya City University Graduate School of Medical Sciences, 1 Kawasumi, Mizuho-cho, Mizuho-ku, Nagoya 467-8601, Japan

Email: ST* - takasato@med.nagoya-cu.ac.jp; HT - takeyama@med.nagoya-cu.ac.jp

* Corresponding author

Received: 31 March 2009 Accepted: 10 June 2009 Published: 29 June 2009

Cases Journal 2009, 2:6714 doi: 10.4076/1757-1626-2-6714

This article is available from: <http://casesjournal.com/casesjournal/article/view/6714>

© 2009 Takayama and Takeyama; licensee Cases Network Ltd.

This is an Open Access article distributed under the terms of the Creative Commons Attribution License (<http://creativecommons.org/licenses/by/3.0>), which permits unrestricted use, distribution, and reproduction in any medium, provided the original work is properly cited.

Abstract

Introduction: We report a case of colonoscopy-assisted laparoscopic sigmoidectomy used for the management of sigmoid volvulus.

Case presentation: We report a 68-year-old female who underwent colonoscopy assisted laparoscopic sigmoidectomy. In this procedure, an anvil is inserted into the anus with colonoscopic assistance. An anastomosis is established without removing the colon from the abdominal cavity, and the maximum incision size is approximately 2 cm, similar to that in laparoscopic cholecystectomy. The risk of infection is lower compared with pure laparoscopic surgery, in which an incision is made for extracting the tissue specimen without opening the colon within the abdominal cavity to maintain anastomosis. The patient was discharged 1 week after surgery without complications.

Conclusions: We believe that this new technique is a feasible approach for the treatment of benign lesions, particularly sigmoid volvulus, which is generally large enough to allow insertion of the anvil.

Introduction

Laparoscopic techniques have become indispensable tools for surgeons. In colonic surgery, laparoscopic procedures are widely performed. Typically, the surgeon withdraws the colon from the abdominal cavity, resects the lesion, attaches an anvil to the oral end of the colon, returns the colon to the abdominal cavity, and then performs an anastomosis of the remaining intestine. This procedure requires an incision larger than 5 cm. Pure laparoscopic anastomosis, in which the colon is not removed from the abdominal cavity, is very difficult to perform. Therefore, laparoscopy often provides no clear advantage over open colectomy. However, in our technique, the maximum

incision size is approximately 2 cm, an obvious advantage over classic laparoscopic surgery.

Case presentation

A 68-year-old yellow raced Japanese female had a chronic history of sigmoid volvulus with persistent constipation due to paralysis of the sigmoid colon. Sigmoidectomy is considered the best therapy for such conditions. The possibility of malignancy and other abdominal diseases was eliminated by performing colonoscopy, abdominal computed tomography, and barium enema. The day before the operation we prepared the colon using 1800 ml isotonic magnesium citrate.

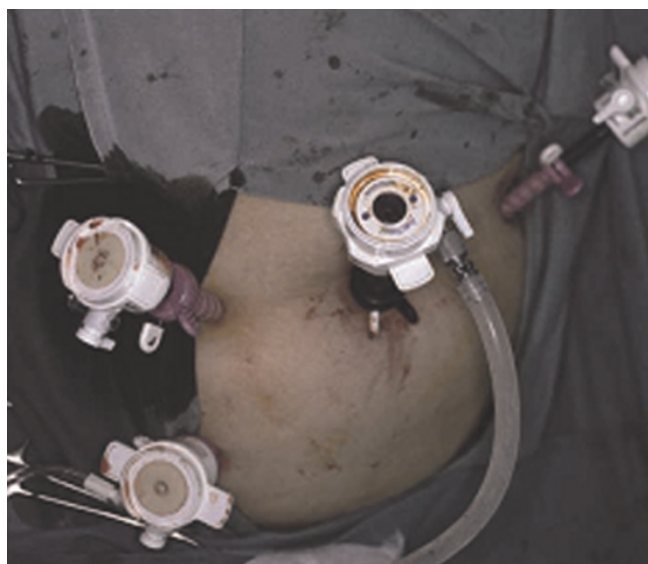

Figure 1. Placement of the four trocars (10, 5, 5, and 5 mm).

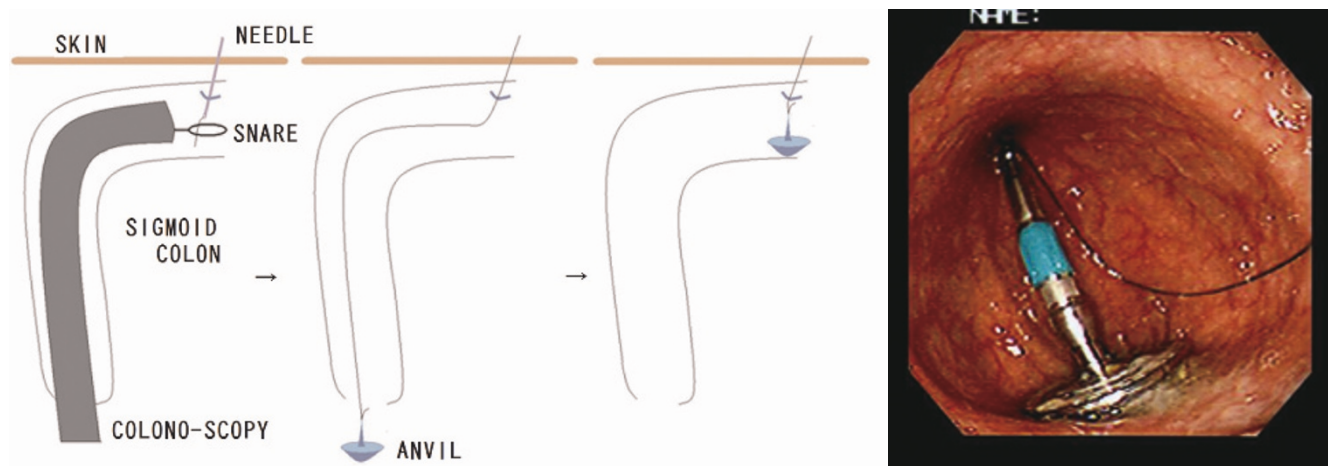
After inducing general anesthesia, the patient was placed in the lithotomy position. The first port (10 mm) was placed near the umbilicus, the second (5 mm) in the left upper quadrant, the third (5 mm) in the right middle flank, and the last (5 mm) in the right lower quadrant (Figure 1). After inserting the trocar, the colonoscope was inserted into the splenic flexure through the anal aperture under colonoscopic and laparoscopic monitoring. The length was sufficient to prevent the recurrence of sigmoid volvulus, which was estimated to be 40 cm in this patient. Intracolonic lavage was performed with polyvinylpyrrolidone iodine, using a colonoscope. First, an 18 G needle

was inserted into the sigmoid colon to the oral cutting point. Through this opening, a 2-0 nylon suture was inserted into the colon. It was retrieved using snare forceps, and the colonoscope was removed from the anus. The anvil was attached to it, allowing it to be pulled back to the sigmoid colon (Figures 2 and 3). The linear stapler was used to cut the anal end of the anvil and the end of the sigmoid colon (Figure 4). The mesosigmoid colon was cut using laparoscopic coagulating shears. Before anastomosis, the anvil was cleaned with iodine. The rest of the colon was anastomosed from the oral side of the anvil to the anal side of the shaft. Finally, the resected sigmoid colon was removed through the umbilical incision. An incision of less than 2 cm was adequate.

Two days after surgery, the patient started eating and her body temperature normalized. The following day, the patient walked comfortably with only slight abdominal pain. Her bowel function improved compared with its preoperative status. One week after surgery, the operative scar healed completely (Figure 5) and the patient was discharged with no complications.

Discussion

Using the technique described here, the size of the operative scar is almost identical to that after laparoscopic cholecystectomy. Benign lesions, sigmoid volvulus, diverticulitis, and inflammatory bowel diseases have been treated with laparoscopic approaches, [1-4] but most of these cases were treated by a method identical to that used in malignant cases, in which the colon is anastomosed outside the abdominal cavity. Large incisions are required for this procedure. This new technique seems to be applicable to several diseases, apart from malignancies, where it is



Figures 2 & 3. The colonoscope was inserted into the sigmoid colon through the anal aperture. An 18 G needle was inserted into the sigmoid colon percutaneously to the oral cutting point. Through this opening, a 2-0 nylon suture was inserted into the colon. It was retrieved using snare forceps and removed from the anus. The anvil was attached to it, allowing it to be pulled back to the sigmoid colon.

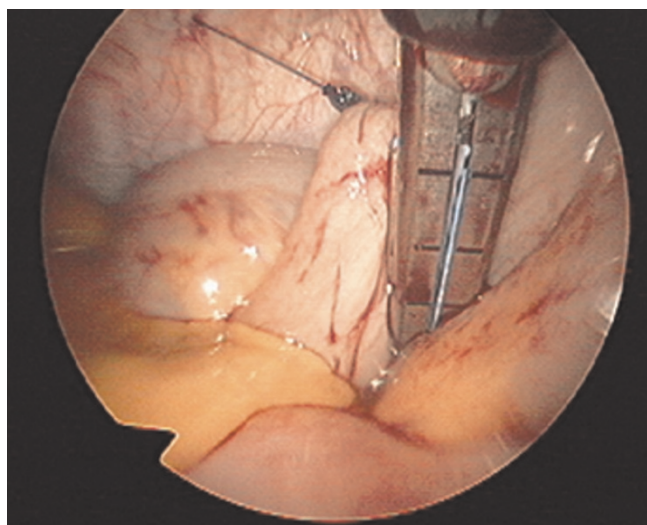


Figure 4. The sigmoid colon was cut with a linear stapler at a point just on the anal side of the anvil.

impossible to remove the colon without incising the tumor. In addition, anastomoses that require the colon to be opened in the intra-abdominal cavity, such as intra-abdominal functional end-to-end anastomosis, are also performed as colonic anastomoses [5]. However, this necessitates opening the colon in the abdominal cavity, and also requires an additional staple line compared with our method. Therefore, our method is superior to functional end-to-end anastomosis and other anastomoses for the view point of risks of infection and leakage.

Conclusions

Several features of malignant growths, such as their size and location, may restrict the application of the method described here. However, this method is feasible in disease

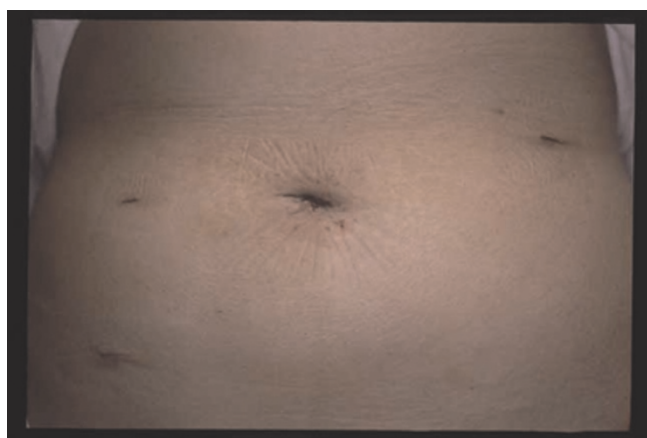


Figure 5. Operative scars after operation.

conditions that have a sufficiently large lumen for anvil insertion. And more this technique may be useful for minimum invasive surgery such as “NOTES” in near future.

Consent

Written informed consent was obtained from the patient for publication of this case report and accompanying images. A copy of the written consent is available for review by the Editor-in-Chief of this journal.

Competing interests

The authors declare that they have no competing interests.

Authors’ contributions

TS contributed to the manuscript as an operator and TH contributed to the manuscript as an assistant operator.

References

1. Bouillot JL, Aouad K, Badawy A, Alamowitch B, Alexandre JH: **Elective laparoscopic-assisted colectomy for diverticular disease. A prospective study in 50 patients.** *Surg Endosc* 1998, **12**:1393-1396.
2. Mooney MJ, Elliott PL, Galapon DB, James LK, Lilac LJ, O’Reilly MJ: **Hand-assisted laparoscopic sigmoidectomy for diverticulitis.** *Dis Colon Rectum* 1998, **5**:630-635.
3. Canin-Endres J, Salky B, Gattorno F, Edey M: **Laparoscopically assisted intestinal resection in 88 patients with Crohn’s disease.** *Surg Endosc* 1999, **6**:595-599.
4. Lee SW, Yoo J, Dujovny N, Sonoda T, Milsom JW: **Laparoscopic vs. hand-assisted laparoscopic sigmoidectomy for diverticulitis.** *Dis Colon Rectum* 2006, **49**:464-469.
5. Sundin JA, Wasson D, McMillen MM, Ballantyne GH: **Laparoscopic-assisted sigmoid colectomy for sigmoid volvulus.** *Surg Laparosc Endosc* 1992, **2**:353-358.

Do you have a case to share?

Submit your case report today

- Rapid peer review
- Fast publication
- PubMed indexing
- Inclusion in Cases Database

Any patient, any case, can teach us something



CASES NETWORK

www.casesnetwork.com