

Case report

Drug induced toxic epidermal necrolysis: two case reportsSyed Nurul Rasool Qadir^{1*}, Naeem Raza² and Fozi Qadir³Addresses: ¹Department of Dermatology, Combined Military Hospital, Kohat-75200, Pakistan²Department of Dermatology, PAF Hospital Faisal, Karachi-8, Pakistan³Department of Emergency Medicine, Military Hospital, Peshawar Road, Rawalpindi-51000, Pakistan

Email: SNRQ* - s_qadir2004@hotmail.com; NR - naeemraza561@hotmail.com; FQ - foziq@hotmail.com

* Corresponding author

Received: 12 May 2009 Accepted: 14 August 2009 Published: 9 September 2009

Cases Journal 2009, **2**:7765 doi: 10.4076/1757-1626-2-7765This article is available from: <http://casesjournal.com/casesjournal/article/view/7765>

© 2009 Qadir et al.; licensee Cases Network Ltd.

This is an Open Access article distributed under the terms of the Creative Commons Attribution License (<http://creativecommons.org/licenses/by/3.0>), which permits unrestricted use, distribution, and reproduction in any medium, provided the original work is properly cited.**Abstract**

Introduction: Among the various drug induced dermatological entities toxic epidermal necrolysis and Stevens-Johnson's syndrome occupy a primary place in terms of mortality. Prompt recognition of these conditions, immediate drug withdrawal and institution of appropriate treatment plays a vital role in reducing mortality. Drugs are by far the most common cause of toxic epidermal necrolysis, in which large sheets of skin are lost from the body surface making redundant the barrier function of the skin, with its resultant complications. The use of systemic corticosteroids in the treatment of toxic epidermal necrolysis has always been controversial, some consider corticosteroids life-saving while others believe that they increase mortality.

Case presentation: We describe two cases of drug-induced toxic epidermal necrolysis, a male and a female, both caucasoids of Pakistani origin, one treated without any steroids and the other with them, who made complete recovery without any major complications or sequelae.

Conclusion: The administration of systemic corticosteroids did not cause any major changes in outcome in our cases.

Introduction

Toxic epidermal necrolysis also known as Lyell's syndrome is a rare but potentially life threatening condition. It is primarily a cutaneous reaction to various precipitating agents, characterized by wide spread erythema and detachment of the epidermis from the dermis. Toxic epidermal necrolysis occurs sporadically, more commonly in adults, with a mean age of 46.8 years. There is no sexual or racial predilection. It is fairly rare with an annual incidence of 1.2 cases per million. An increased incidence has been observed in HLA-B 12 individuals.

Case presentation**Case report I**

A 60-year-old Pakistani male of Caucasoid origin was admitted to the dermatology unit with the following history. He had been operated for cataract 05 days ago. Post-operatively Co-trimoxazole tablets were given. Forty eight hours after taking the tablets the patient developed a severe burning sensation all over the body. This was followed by peeling of sheets of skin over the back, buttocks, thighs and neck. He had had a similar reaction to tetracyclines 12 years ago.

Initial examination revealed an asthenic, sick looking man with a B.P. of 130/90 mmHg, temperature 99 degree Fahrenheit and pulse 110/min. Hydration was poor. He was in obvious distress but conscious and oriented. On dermatological examination 40% of body surface area showed peeling of skin in sheets of more than 3 cm leaving behind superficial erosions. The back, buttocks, thighs and anterior aspect of the neck were primarily involved (Figure 1). Skin tenderness and Nickolsky's sign were positive. The mucosae were not involved.

At the time of admission the bio-chemical profile was urea 9 mmol/lit, creatinine 274 umol/lit, potassium 3.6 mmol/lit, and sodium 137 mmol/lit. The serum total proteins were 4.9 mg/dl with an albumin level of 3.4 mg/dl and an albumin/globulin ratio of 1.5/1. The blood counts, urinalysis, electrocardiogram and chest roentogram were unremarkable. Skin biopsy showed a sub-epidermal split with necrosis of the epidermis and eosinophilic infiltration.

On the basis of body surface area involved a fluid requirement of 4 lit/24 hours was deduced, half of which was administered as Ringer's lactate and the other half as glucose saline. He was also put on intravenous Ceftriaxone 1 gm twice daily. The urinary out-put improved and temperature returned to normal. Blood chemistry repeated on the 3rd day revealed no abnormality. The very next day the patient developed multiple purpuric and ecchymotic spots over both thighs. Urgent investigations revealed raised fibrinogen degradation products levels in both urine and blood; however the serum fibrinogen, platelets and bleeding profile were normal. A diagnosis of compensated disseminated

intravascular coagulation was made and fresh frozen plasma transfused. Over the next couple of days the skin lesions subsided and fibrinogen degradation products levels returned to normal. Subsequently the patient made an uneventful recovery and all the lesions healed without scarring.

Case report 2

A 45-year-old Pakistani female of Caucasoid origin was admitted to the dermatology ward with extensive peeling of skin over the back and buttocks. She had taken a quinolone (moxifloxacin) for fever 05 days ago which was followed by a morbilliform eruption and widespread peeling of skin. She was a known diabetic for the past 10 years on insulin injections. On examination she was conscious but distressed, dehydrated and febrile with a temperature of 101 degree Fahrenheit, B.P. 130/90, pulse 98/min. She had skin peeling involving about 60% of the body surface area including the back, buttocks, face, neck and limbs (Figures 2-4). Oral and conjunctival mucosae were severely involved (Figures 5 and 6) and Nickolsky's sign and skin tenderness were positive. Biochemical profile revealed raised serum urea 10.7 mmol/lit, creatinine 75 umol/lit, sodium 137 mmol/lit, potassium 3.8 mmol/lit, her ALT was also raised 87 IU but serum bilirubin and alkaline phosphatase were within normal limits. The blood counts, urinalysis, X-rays chest and electrocardiogram revealed no abnormality. Skin biopsy showed sub-epidermal clefting with a mixed infiltrate of polymorphs. The patient was treated with intravenous dexamethasone 3 mg 8 hourly and intravenous ceftriaxone 1 gm twice daily, intravenous insulin on a sliding scale along with topical antiseptic dressings and fluid and electrolyte replacement therapy. The steroids were gradually tapered off and the patient exhibited an uneventful



Figure 1. Peeling of sheets of skin and erosions over the buttocks (Case no. 1).

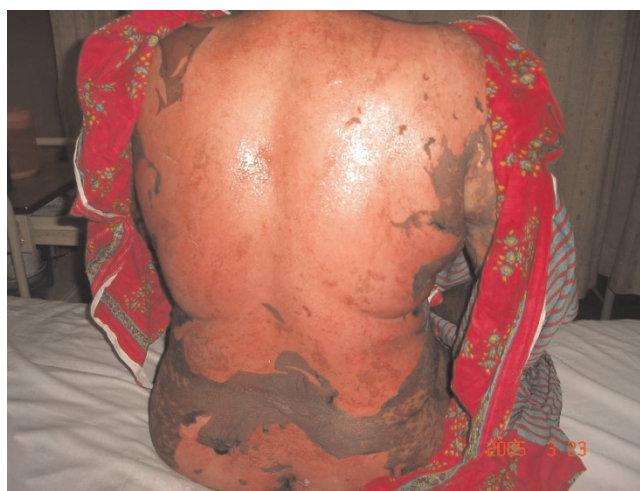

Figure 2. Peeled skin over the back and buttocks (Case no 2).

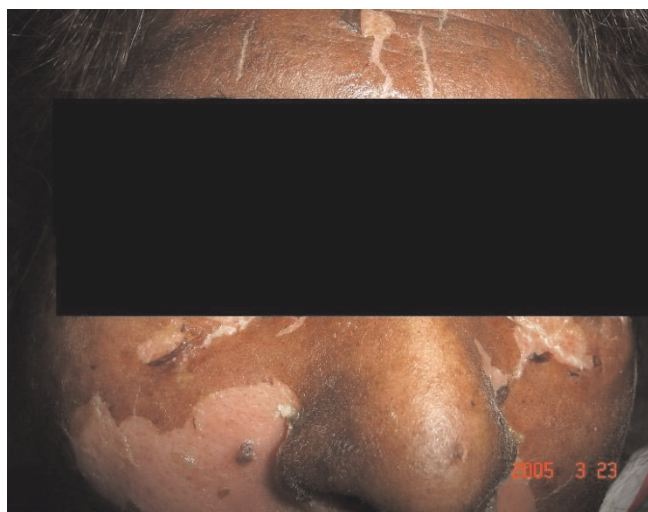

Figure 3. Involvement of the face (Case no. 2).

recovery over the next 2 weeks; all the skin lesions healed without scarring and there were no sequelae except for a corneal opacity in the right eye.

Discussion

Toxic epidermal necrolysis also known as Lyell's syndrome was first described by Lyell in 1956. The word toxic alludes to the constitutional symptoms while necrolysis refers to the necrosis and detachment of the full thickness of the epidermis [1].

Drugs are the most common cause accounting for about 65%-80% of the cases. The most common offending agents are sulfonamides, NSAIDs, butazones and hydrantoin [2]. The risks related to different drugs are different

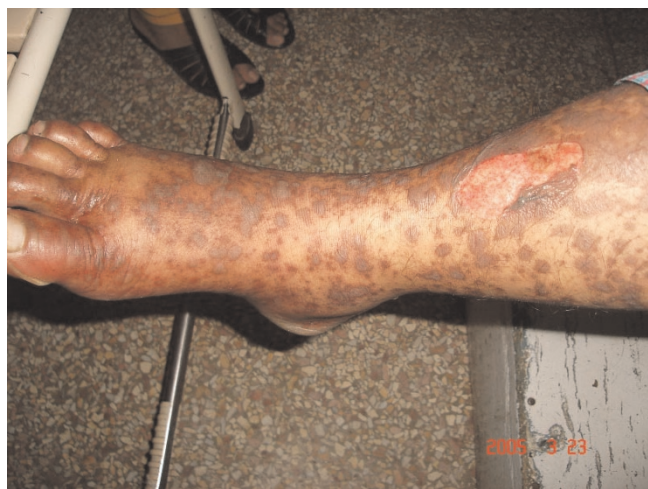

Figure 4. Rash and erosion over the lower limb (Case no. 2).

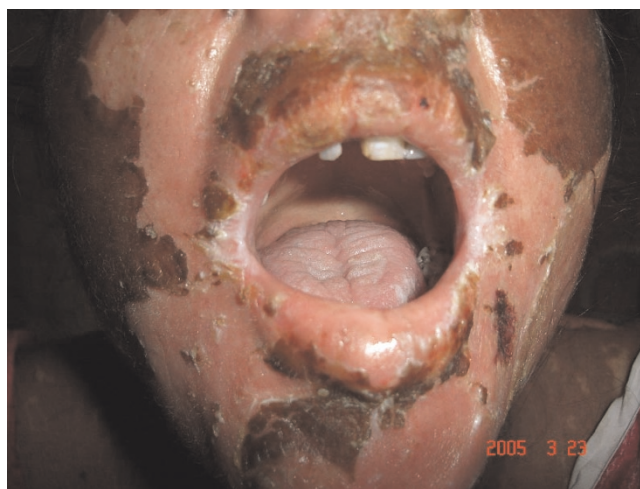

Figure 5. Involvement of the oral mucosa (Case no. 2).

even for closely chemically related products. Multiple precipitating causes may co-exist [3]. The earlier a causative agent is withdrawn the better is the prognosis. Patients on drugs with longer half-lives have an increased chance of dying [4]. An increased incidence of toxic epidermal necrolysis has been observed in patients with brain tumors, systemic lupus erythematosus, acquired immune deficiency syndrome and high dose steroid therapy [5]. Other precipitating causes include viruses, bacteria, fungi, immunization, neoplasms, graft versus host disease, radiotherapy, beverages fumigants and idiopathic.

An immune mechanism is implicated in the pathogenesis but its nature is still unclear. It is primarily directed at drug modified epidermal cells [5]. Different immuno-inflammatory pathways with early participation of activated CD8 T-lymphocytes are involved. Blister fluid contains significantly higher levels of soluble interleukin-2 receptors (sIL-2R) probably related to a local down-regulation of an immune mediated cytotoxic reaction [6].

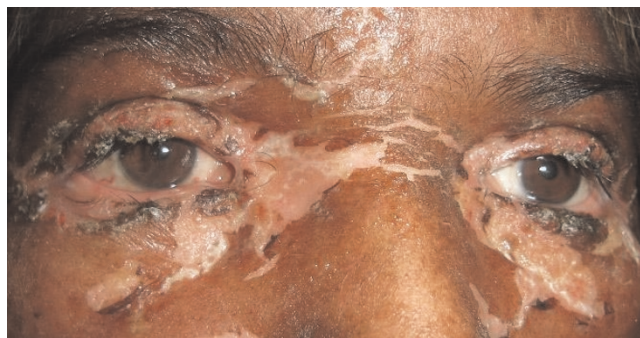


Figure 6. Involvement of the conjunctival mucosa (Case no. 2).

Microscopically, there is sub-epidermal bullae formation, with eosinophilic epidermal necrosis. The dermal vessels show endothelial swelling without any vasculitis or necrosis. Ultra-structurally there is damage to the basal and lower spinous levels of the epidermis and cleft formation at the lamina densa. Immuno-florescence is always negative [7].

The interval between the intake of a drug and the onset of symptoms generally ranges from a few hours to 22 days with a maximum of 38 days recorded in case of anti-tuberculosis drugs [8].

There is a prodromal phase in which there is burning sensation all over the skin and conjunctivae, along with skin tenderness, fever, malaise and arthralgias. This is followed by the eruptive phase in which a morbilliform rash erupts in the axillae and groins and rapidly becomes confluent into a pale, livid, confluent erythema, sparing only the hairy areas. In the acme or peak phase, vesicles and flaccid bullae appear which rupture quickly to leave denuded areas mainly at pressure points. Fluid and protein loss occurs as in 2nd degree burns. Nickolsky's sign is positive in erythematous skin.

As a rule oral, genital and anal mucous membranes are severely involved. Nail shedding and hair loss may occur. Mucous membrane involvement occurs in 85%-95% cases and precedes the skin involvement in one third of cases [5].

The following diagnostic criteria must be fulfilled for a case to be labeled as toxic epidermal necrolysis.

1. Bullae or erosions involving more than 20% of body surface area or three different anatomical sites.
2. Skin peeling in sheets of more than 3 cm.
3. Involvement of non-exposed skin.
4. Mucous membranes frequently involved.
5. Skin tenderness within 48 hours of rash.
6. Biopsy confirmation within 48 hours.
7. Fever.
8. Bullae arising on an erythematous background.
9. Exclusion of Staphylococcal scalded skin syndrome.

Investigations usually show leukocytosis, albuminuria, water and electrolyte imbalance and raised transaminases.

Leukopenia and thrombocytopenia occur in some cases. Lymphopenia with selective depression of CD4 T-helper cells may occur.

Complications include hypovolemic shock, pulmonary edema, acute tubular necrosis, membranous glomerulonephritis, gastrointestinal hemorrhage, bronchopneumonia and disseminated intravascular coagulation. Cicatricial alopecia, anonychia, ectropion, entropion and corneal opacities can also occur.

Recovery is slow over a period of 14-28 days and relapses are frequent. There is a tendency for scarring in all but the mildest of cases. Mortality is 25%-50% and rises with age, being more than 50% above 60 years of age. Half the deaths occur due to secondary infection. Pulmonary edema, pulmonary embolism and gastrointestinal hemorrhage are other important causes of mortality. Sequelae occur in 40% of cases and are mainly ocular such as ectropion, entropion, synechiae, pannus formation and sicca syndrome. Reticulate skin pigmentation may occur over the affected areas [5].

Treatment is mainly supportive with removal of the precipitating agent, good nursing care preferably on a ripple bed, care of the eyes and mouth to prevent scarring and infection and maintenance of fluid and electrolyte balance. Intravenous fluids given during the first 24 hours should include 1 ml/kg/% of body surface area involved of macromolecules (albumin), plus 0.7 ml/kg/% surface area of isotonic saline. In addition 1500 ml of fluids should be given through the naso-gastric tube during the first 24 hours. Intravenous fluids should be supplemented with potassium.

The patient should be put on a high protein diet 2-3 gms/kg daily. At least 2000 cal should be given during the first 24 hours increasing by 500 cal/day upto a maximum of 4000 cal/day. Naso-gastric feeding is preferable in severely ill patients. Temperature should be maintained at 30-32 degree Celsius. Topical Chlorhexidine or Silver nitrate may be used to wash denuded areas. Silver sulfadiazine should be avoided due to the implications of sulfonamides in toxic epidermal necrolysis [9].

Anti-coagulation with Heparin for the duration of the hospital stay has been advocated [5]. Some authorities advocate immediate covering of denuded areas with biologic dressings like porcine xenografts, cryopreserved allografts or amnion and collagen based skin substitutes [10].

The role of steroids is controversial. Their efficacy has never been conclusively demonstrated. A number of cases of toxic epidermal necrolysis have occurred in patients

who were already on high-dose steroids [11]. Retrospective studies indicate a higher death rate in patients on steroids and that steroids do not prevent the occurrence or extension of epidermal necrolysis [12]. Another study has reported 66% survival rate in patients managed without steroids as compared to a 33% survival in patients on steroid therapy. The former group had a decreased incidence of gastrointestinal ulceration, candidal infection and better recovery rate from septic complications [13].

Early infusion of high-dose Intravenous Immunoglobulins (IVIG) causes a rapid cessation of skin and mucosal detachment in a majority of patients [7]. According to a study patients treated with IVIG have 83% less chance of dying than those not treated with it [14]. Contrarily another study has shown no beneficial effect of IVIG therapy [15].

Abbreviations

HLA, human leukocyte antigen; IVIG, intravenous immunoglobulins; NSAIDs, non steroidal anti inflammatory drugs.

Consent

Written informed consent was obtained from the patients for the publication of these case reports and the accompanying images. A copy of the consent is available for review from the journal's Editor-in-Chief.

Competing interests

The authors declare that they have no competing interests.

Authors' contributions

SNRQ played a primary role in conceiving the case reports and in the initial diagnosis and management of the patients. NR contributed significantly to the final draft of the manuscript and the review of literature. FQ had important inputs in the managements of the patients as well as the case reports.

References

1. Hurwitz RM, Rivera HP, Gooch MH, Slama TG, Handt A, Weiss J: **Toxic shock syndrome or Toxic epidermal necrolysis? Case reports showing clinical similarity and histological separation.** *J Am Acad Dermatol* 1982, **7**:246-254.
2. Guillaume JC, Roujeau JC, Revuz J, Penso D, Touraine R: **The culprit drugs in 87 cases of toxic epidermal necrolysis (Lyell's syndrome).** *Arch Dermatol* 1987, **123**:1166-1170.
3. Stern RS, Chan HL: **Usefulness of case report literature in determining drugs responsible for toxic epidermal necrolysis.** *J Am Acad Dermatol* 1989, **21**:317-322.
4. Garcia-Doval I, Le Cleach L, Bocquet H, Otero XL, Roujeau JC: **Toxic epidermal necrolysis and Stevens-Johnson syndrome: does early withdrawal of causative drugs decrease the risk of death.** *Arch Dermatol* 2000, **136**:323-327.
5. Roujeau JC, Chosidow O, Saiag P, Guillaume JC: **Toxic epidermal necrolysis (Lyell's syndrome).** *J Am Acad Dermatol* 1990, **23**:1039-1058.
6. Correia O, Delgado L, Roujeau JC, LeCleach L, Flemming-Torrinha JA: **Soluble interleukin 2 receptor and interleukin 1-alpha in**

Toxic epidermal necrolysis: a comparative analysis of serum and blister fluid samples. *Arch Dermatol* 2002, **138**:29-32.

7. Revuz J, Penso D, Roujeau JC: **Toxic epidermal necrolysis: clinical findings and prognostic factors in 87 patients.** *Arch Dermatol* 1987, **123**:1160-1165.
8. Bork K: **Toxic epidermal necrolysis (Lyell's syndrome).** In *Cutaneous side-effects of drugs*. 1st edition. Edited by Chapman LE. Philadelphia: WB Saunders & Co; 1988:122-132.
9. Roujeau JC, Revuz J: **Intensive care in dermatology.** In *Recent advances in dermatology*. 8th edition. Edited by Champion RH, Pye RJ. Edinburgh: Churchill-Livingstone; 1990:85-99.
10. Revuz J, Roujeau JC, Guillaume JC, Penso D, Touraine R: **Treatment of toxic epidermal necrolysis: Creteil's experience.** *Arch Dermatol* 1987, **123**:1156-1158.
11. Guibal F, Bastuji-Garin D, Chosidow O, Saiag P, Revuz J, Roujeau JC: **Characteristics of toxic epidermal necrolysis in patients undergoing long-term glucocorticoid therapy.** *Arch Dermatol* 1995, **131**:669-672.
12. Heimbach DM, Engrav LH, Marvin JA, Harnar TJ, Grube BJ: **Toxic epidermal necrolysis: a step forward in treatment.** *JAMA* 1987, **257**:2171-2175.
13. Halebian PH, Carder VJ, Madden MR, Finklestein JL, Shires GT: **Improved burn center survival in patients with toxic epidermal necrolysis managed without corticosteroids.** *Ann Surg* 1986, **204**:503-512.
14. Prins C, Kerdel FA, Padilla RS, Hunziker T, Chimenti S, Viard I, Mauri DN, Flynn K, Trent J, Margolis DJ, Saurat JH, French LE: **Treatment of toxic epidermal necrolysis with high-dose intravenous immunoglobulins: Multicenter retrospective analysis of 48 consecutive cases.** *Arch Dermatol* 2003, **139**:26-32.
15. Trent JT, Kisner RS, Romanelli P, Kerdel FA: **Analysis of intravenous immunoglobulins for treatment of toxic epidermal necrolysis using SCORTEN.** *Arch Dermatol* 2003, **139**:39-43.

Do you have a case to share?

Submit your case report today

- Rapid peer review
- Fast publication
- PubMed indexing
- Inclusion in Cases Database

Any patient, any case, can teach us something



**CASES
NETWORK**

www.casesnetwork.com