

Case report

Transmural migration of a surgical compress into the stomach after splenectomy: a case reportSami Akbulut^{1*}, Mert Mahsuni Sevinc¹, Fatih Basak², Sefika Aksoy²
and Bahri Cakabay¹Addresses: ¹Department of Surgery, Diyarbakir Education and Research Hospital, Op. Dr. Seref Inaloz Caddesi 21400, Diyarbakir, Turkey²Department of Surgery, Istanbul Education and Research Hospital, K.M. Pasa, 34321, Istanbul, Turkey

Email: SA* - akbulutsami@gmail.com; MMS - mahsunisevinc@yahoo.co.uk; FB - fatihbasak@hotmail.com; SA - sefikaaksoy@gmail.com; BC - surgeonbahri@gmail.com

* Corresponding author

Received: 26 May 2009 Accepted: 8 July 2009 Published: 30 July 2009

Cases Journal 2009, **2**:7975 doi: 10.4076/1757-1626-2-7975This article is available from: <http://casesjournal.com/casesjournal/article/view/7975>

© 2009 Akbulut et al.; licensee Cases Network Ltd.

This is an Open Access article distributed under the terms of the Creative Commons Attribution License (<http://creativecommons.org/licenses/by/3.0>), which permits unrestricted use, distribution, and reproduction in any medium, provided the original work is properly cited.**Abstract**

A surgical compress retained in the abdominal cavity following surgery is a serious problem. Here, we describe a 33-year-old female who was admitted with abdominal pain, vomiting, no passage of gas or feces, and abdominal distension for 3 days. She had a splenectomy at another medical center 4 years previously. An upright plain abdominal film revealed small bowel obstruction with marked small bowel air-fluid levels. The physical examination revealed muscular guarding and rebound tenderness in the periumbilical region. Therefore, a laparotomy was performed. A surgical compress was removed at enterotomy and the final diagnosis was gossypiboma. Because a retained surgical compress may lead to medicolegal problems, it is important to count the material used before and after a surgical procedure to reduce the risk of this problem.

Introduction

Gossypiboma is the term used to describe a surgical swab retained after surgery. Synonyms are textiloma and cottonoid [1]. Fortunately, cases where instruments or sponges are left behind following a surgical procedure are uncommon, although they are potentially dangerous medical errors [2,3]. The literature estimates that a foreign body is retained after intra-abdominal surgery in 1:1,000 to 1:1,500 cases [2,3]. Here, we present a case of transgastric gossypiboma after a splenectomy 4 years previously.

Case presentation

A 33-year-old Turkish woman was admitted to our emergency unit with abdominal pain, severe nausea and vomiting, constipation, no passage of gas or feces, and abdominal distension for 3 days. She had a splenectomy at another center 4 years previously. The previous year, endoscopy had been performed because of dyspepsia and stomach ache. A peptic ulcer crater and a mass compatible with a phytobezoar in the duodenum were observed via endoscopy (Figure 1). Laboratory investigations showed blood urea nitrogen at 38 mg/dl, creatinine at 1.2 mg/dl,

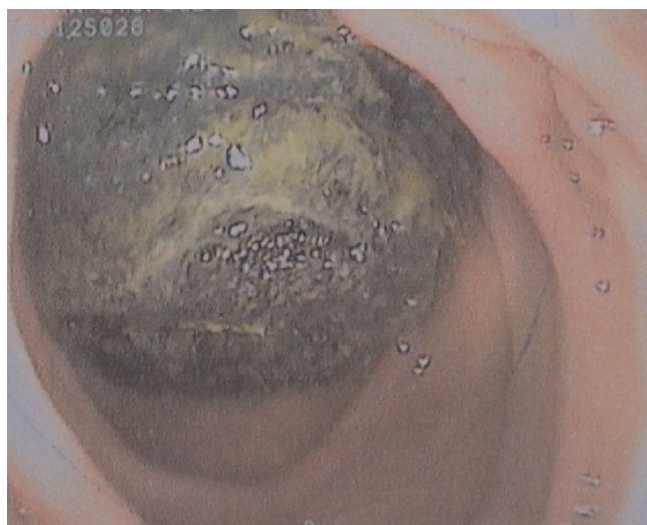


Figure 1. A mass compatible with a phytobezoar was observed in the duodenum via endoscopy.

and C-reactive protein at 45 mg/l. The blood cell count revealed leukocytosis at 17,500/ μ l, with a hemoglobin level of 12.9 g/dl, and a platelet count of 327,000/ μ l. Other serum parameters were within normal limits. The physical examination revealed muscular guarding and rebound tenderness in the periumbilical region. An upright plain abdominal film revealed small bowel obstruction with marked small bowel air-fluid levels. No pathological findings were observed via ultrasound because of distension. The patient underwent an emergency laparotomy with a midline incision. At laparotomy, a mass was observed obstructing the intestine completely 150 cm distal to the ligament of Treitz (Figure 2). A 15 × 20 cm surgical compress was removed at enterotomy

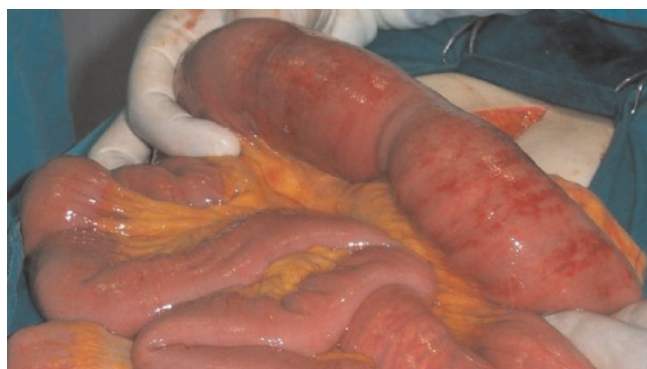

Figure 2. A mass obstructing the lumen of the ileum was observed during laparotomy.

(Figure 3a, 3b, 3c). The patient had an uneventful postoperative course and was discharged on the fifth postoperative day.

Discussion

Postoperative surgical complications are frequently unavoidable. However, some complications result from human error in both the intra- and postoperative periods. One such complication, which is frequently under-reported, is a retained compress or gossypiboma [4]. Retained surgical sponges can cause serious consequences, such as bowel or visceral perforation, obstruction or fistula formation, sepsis, or even death [2,5]. Intra-abdominal gossypibomas can migrate into the ileum, stomach, colon, or bladder without any apparent opening in the wall of these luminal organs [6]. Once in the gastrointestinal system, they cannot pass through the ileocecal valve and cause complete or incomplete intestinal obstruction at this level [7]. In this case, a surgical compress was observed in an ulcerative lesion where it had passed through the stomach wall. It took the compress about one year to pass from the stomach and cause obstruction in the ileum. No abscess or fistula in the abdomen was found.

Gossypiboma is difficult to diagnose, but plain X-rays, ultrasonography (US), computed tomography (CT), and magnetic resonance imaging (MRI) can help to make the diagnosis [8]. In this case, air-water levels were observed via plain X-ray, whereas no pathological finding was observed via US. Typically, gossypibomas are discovered in the first few postoperative days, although they may remain undetected for many years. Bowel obstruction, perforation, pseudotumor, and peritonitis are the most common clinical presentations, although in some cases constitutional symptoms prevail [9]. Tumerve *et al.* [10] examined 10 cases: eight involved sponges and two involved clamps. In their series, the patients first became symptomatic between 15 days and 20 months postoperatively. Five of their patients had previous Caesarean sections or hysterectomies. Yildirim *et al.* [11] investigated 14 patients who were between 25 and 79 years of age. In their group, the initial complaints began between 5 days and 40 years postoperatively (the last case was an open cholecystectomy). Most of the patients were admitted to hospital with abdominal pain or intestinal obstruction. In our case, the obstruction developed 4 years postoperatively.

In conclusion, small sponges should not be used during laparotomy. Compresses should only be used intra-peritoneally, one at a time, mounted on forceps. Before closing the peritoneum, the surgeon should explore the abdominal cavity completely.

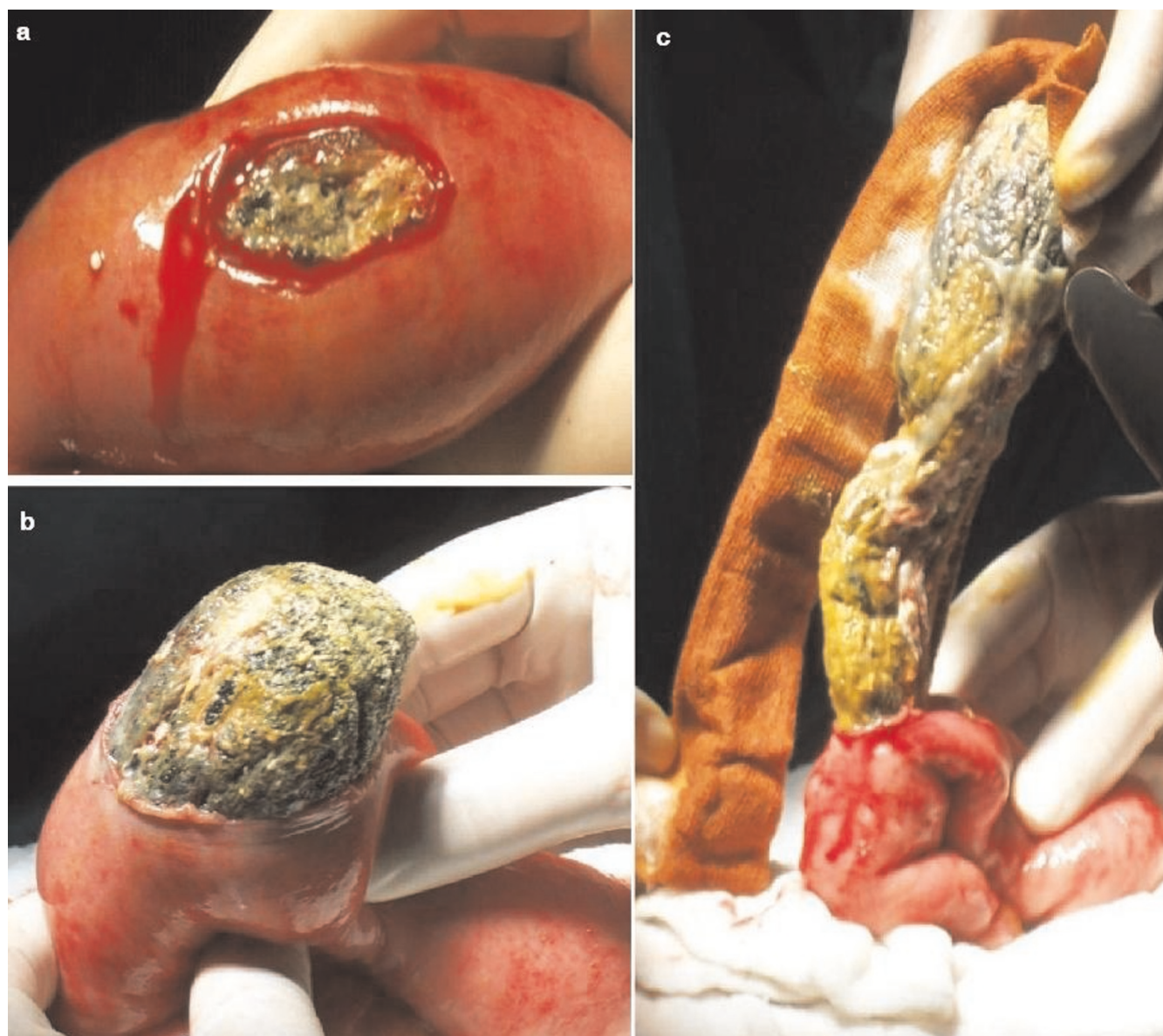

Figure 3a, b and c. The compress was removed at enterotomy.

Abbreviations

CT, Computed tomography; MRI, Magnetic resonance imaging; US, Ultrasonography.

Consent

Written informed consent was obtained from the patient for publication of this case report and accompanying image. A copy of the written consent is available for review by the Editor-in-Chief of this journal.

Competing interests

The authors declare that they have no competing interests.

Author's contributions

FB, SY and MM performed surgical procedure; SA and BC contributed writing the article and review of the literature as well as undertaking a comprehensive literature search; SA contributed design and manuscript preparation.

References

1. Rajagopal A, Martin J: **Gossypiboma "a surgeon's legacy": report of a case and review of the literature.** *Dis Colon Rectum* 2002, **45**:119-120.
2. Gwande AA, Studdert DM, Orav JE, Brennan TA, Zinner MJ: **Risk factors for retained instruments and sponges after surgery.** *N Engl J Med* 2003, **348**:229-235.

3. Rappaport W, Haynes K: **The retained surgical sponge following intra-abdominal surgery. A continuing problem.** *Arch Surg* 1990, **125**:405-407.
4. Kiernan F, Joyce M, Byrnes CK, O'Grady H, Keane FB, Neary P: **Gossypiboma: a case report and review of the literature.** *Ir J Med Sci* 2008, **177**:389-391.
5. Gonzalez-Ojeda A, Rodriguez-Alcantar DA, Arenas-Marquez H, Sanchez Perez-Verdia E, Chavez-Perez R, Alvarez-Quintero R, Perea-Sanchez A: **Retained foreign bodies following intra-abdominal surgery.** *Hepatogastroenterology* 1999, **46**:808-812.
6. Silva CS, Caetano MR, Silva EA, Falco L, Murta EF: **Complete migration of retained surgical sponge into ileum without sign of open intestinal wall.** *Arch Gynecol Obstet* 2001, **265**:103-104.
7. Wig JD, Goenka MK, Suri S, Sudhakar PJ, Vaiphei K: **Retained surgical sponge: an unusual cause of intestinal obstruction.** *J Clin Gastroenterol* 1997, **24**:57-58.
8. Prasad S, Krishnan A, Limdi J, Patankar T: **Imaging features of gossypiboma: report of two cases.** *J Postgrad Med* 1999, **45**:18-19.
9. Lourenco SC, Baptista A, Pacheco H, Malhado J: **A misplaced surgical towel - a rare cause of fever of unknown origin.** *Eur J Intern Med* 2008, **19**:377-378.
10. Tumer AR, Yasti AC: **Medical and legal evaluations of the retained foreign bodies in Turkey.** *Leg Med (Tokyo)* 2005, **7**:311-313.
11. Yildirim S, Tarim A, Nursal TZ, Yildirim T, Caliskan K, Torer N, Karagulle E, Noyan T, Moray G, Haberal M: **Retained surgical sponge (gossypiboma) after intraabdominal or retroperitoneal surgery: 14 cases treated at a single center.** *Langenbecks Arch Surg* 2006, **391**:390-395.

Do you have a case to share?

Submit your case report today

- Rapid peer review
- Fast publication
- PubMed indexing
- Inclusion in Cases Database

Any patient, any case, can teach us something



**CASES
NETWORK**

www.casesnetwork.com